

NINA M.C. MATHIJSEN

**NOVEL  
PERSPECTIVES  
TO IMPROVE THE  
OUTCOME  
OF BONE  
IMPACTION  
GRAFTING IN  
REVISION SURGERY  
OF TOTAL HIP  
ARTHROPLASTIES**

This study was made possible by the support of BISLIFE Foundation.



**Cover** Esther Ris, Proefschriftomslag.nl

**Layout** Renate Siebes, Proefschrift.nu

**Printed by** Ridderprint, Ridderkerk

**ISBN** 978-94-90791-23-0

**Copyright © 2014, N.M.C. Mathijssen**

All rights reserved. No part of this book may be reproduced or transmitted in any form by any means, without prior written permission of the author.

# **Novel perspectives to improve the outcome of bone impaction grafting in revision surgery of total hip arthroplasties**

## **PROEFSCHRIFT**

ter verkrijging van de graad van doctor  
aan de Radboud Universiteit Nijmegen  
op gezag van de Rector Magnificus prof. mr. S.C.J.J. Kortmann,  
volgens besluit van het college van decanen  
in het openbaar te verdedigen op maandag 13 januari 2014  
om 16.30 uur precies

door

**Nina Maria Cornelia Mathijssen**

geboren op 3 mei 1980  
te Breda

**Promotor:**

Prof. dr. P. Buma

**Copromotoren:**

Dr. R.M. Bloem

Dr. B.W. Schreurs

Dr. P. Pilot

**Manuscriptcommissie:**

Prof. dr. M.A.W. Merkk

Prof. dr. J. Jansen

Prof. dr. G.H.I.M. Walenkamp (MUMC)

# Contents

<b>Chapter 1</b>	Review of literature and aim of this thesis	7
<b>Chapter 2</b>	Combining bisphosphonates with allograft bone for implant fixation: A review	27
<b>Chapter 3</b>	Impregnation of bone chips with alendronate and cefazolin, combined with demineralized bone matrix: A bone chamber study in goats	41
<b>Chapter 4</b>	Comparison of contamination of femoral heads and pre-processed bone chips during hip revision arthroplasty	61
<b>Chapter 5</b>	Impregnation of bone chips with antibiotics and storage of antibiotics at different temperatures: An <i>in vitro</i> study	73
<b>Chapter 6</b>	The effect of door-openings on numbers of colony forming units in the operating room in hip revision surgery	89
<b>Chapter 7</b>	DEXA and hip revision arthroplasty with bone impaction grafting	101
<b>Chapter 8</b>	General discussion	113
	English summary	134
	Nederlandse samenvatting	137
	Dankwoord	140
	Curriculum vitae	143



## CHAPTER 1

# REVIEW OF LITERATURE AND AIM OF THIS THESIS

Mrs. A.B. is a 68 year old woman who received a primary total hip arthroplasty (THA) for a painful osteoarthritis of her hip 14 years ago. She was very satisfied with the hip replacement; the pain in her hip had disappeared and she regained the ability to walk and cycle again, two of her favorite hobbies. However, 3 years ago the pain in her hip returned and physical activity became increasingly difficult again. Finally, her discomfort when walking or cycling forced her to visit her orthopedic surgeon. An X-ray revealed a loose prosthesis with bone loss around the acetabulum and proximal femur. The orthopedic surgeon and the patient decided for a hip revision surgery. During the surgery, both the acetabular and femur component of the hip prosthesis were replaced by a new implant and the bone loss was restored with bone from a bone bank. The surgery lasted 4 hours and had a great impact on Mrs. A.B. During the surgery she had 1.5 liters of blood loss. Postoperatively she developed a wound infection for which she had to stay in the hospital for 6 more weeks. She was treated with intravenous antibiotics and surgical debridement of the infected area. Moreover, rehabilitation for this second surgery was much longer when compared to the first hip replacement. At this moment, 1 year after the hip revision surgery, she is satisfied with the outcome and will be monitored by her orthopedic surgeon yearly.

## **Osteoarthritis and total hip arthroplasty**

Osteoarthritis refers to a clinical syndrome of joint pain accompanied by varying degrees of functional limitation and reduced quality of life [1]. It is characterized by progressive pathological changes of the articular cartilage [1, 2]. These changes include localized loss of cartilage and remodeling of subchondral and adjacent bone with new bone formation (osteophyte) at the joint margins. The cause of this disorder is not completely understood, but forces that place high biomechanical stresses on the joints (bearing weight, postural or orthopedic abnormalities) or injuries that cause chronic irritation of the bone are thought to interact with biochemical and genetic factors to contribute to osteoarthritis [1, 2]. Symptoms of osteoarthritis include pain, reduced function, stiffness, instability and disability. Osteoarthritis is the most common disease of joints and is responsible for considerable morbidity [1]. It affects about 8 million people in the United Kingdom and nearly 27 million people in the United States. In the Netherlands, an estimated 657,000 people have osteoarthritis (2007, osteoarthritis of the hip or other joints) [3]. However, the exact incidence and prevalence of osteoarthritis is difficult to determine because the early structural changes of the articular cartilage associated with osteoarthritis are



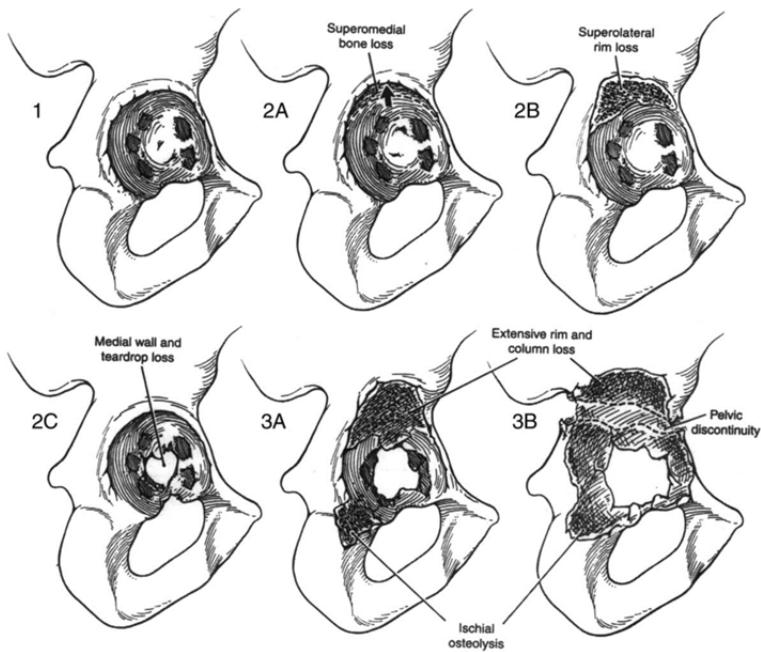
preceding clinical symptoms and thus are not detected in most cases in an early stage of the disease [1, 2].

The first attempts to treat patients with osteoarthritis of the hip surgically, by replacing the diseased joint by a THA, were performed more than 100 years ago. Since the 1960s, success rates of the surgical treatment of osteoarthritis of the hip joint increased greatly [2, 4, 5]. Nowadays, yearly about 25,000 THAs are performed in The Netherlands and more than 500,000 THA procedures are done every year in the UK and USA [4]. Results of these THA procedures are excellent; clinical outcomes show greater than 95% survivorship at 10-year follow up and greater than 80% at 25-year follow up [4]. Quality of life of the patient with osteoarthritis of the hip increases greatly after this procedure. As a result of the success and the ageing population, the number of THA procedures has increased the last decades. Also, this procedure is performed in increasingly younger and more active patients which also leads to increased numbers of THAs annually [6].

### **Hip revision arthroplasty and bone impaction grafting**

Mechanical loosening is one of the most common causes of failure of a primary THA [6] and occurs secondary to a chronic, granulomatous, inflammatory response that is stimulated and maintained by implant-derived wear particles [7, 8]. This process is complex and involves the interactions of numerous cytokines, chemokines and growth factors [9]. These affect the osteoclasts at distinct stages of their development and imbalance between osteoclast and osteoblast activity may arise. This might lead to a localized or systemic reduction in bone mass [9]. A classification of loss of bone stock around the implant is proposed by Paprosky et al. [10] (Figure 1.1). After failure of a primary THA, a more challenging and costly hip revision surgery is needed, mainly due to management of the bone stock loss. In the Netherlands, 11,283 patients received a hip revision surgery from 2007 to 2011 [11]. Patients undergoing hip revision surgery have a longer hospital stay, an increased risk of complications and costs are at least 35% more when compared to primary hip arthroplasty [12]. Survival rates of revision THAs are good, but the longevity is generally lower than that of primary THAs [13]. Survival rates in literature differ from 35% to 100% at 10 years [13-16]. These large differences can be explained by the heterogeneity of revision surgery.

One of the techniques to restore the bone stock around the implant is bone impaction grafting (BIG, Figure 1.2) [14]. With BIG, first, the defects in acetabulum and femur can



**Figure 1.1** Illustration depicting the Paprosky acetabular defect classification system, obtained from Weeden et al. [107].

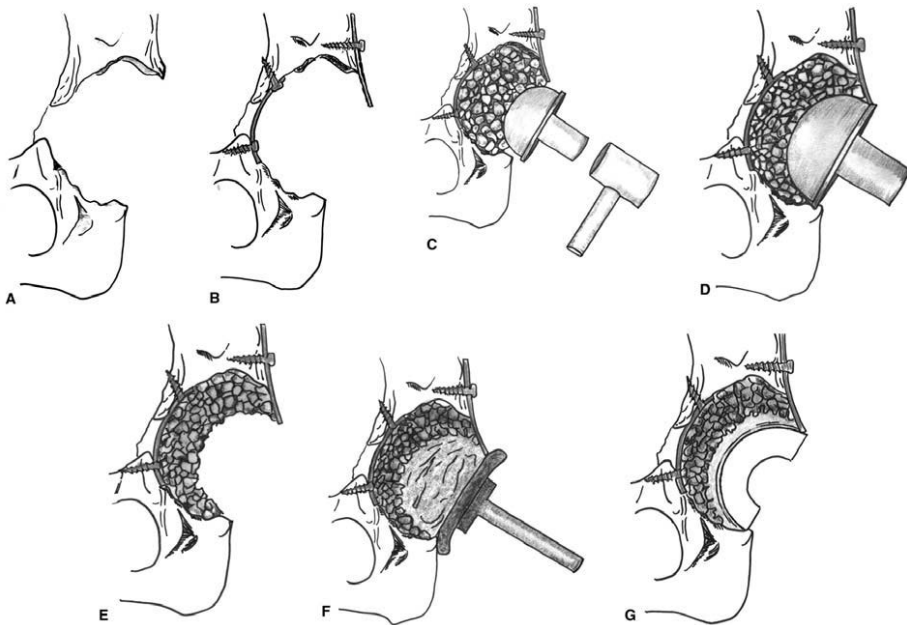
Type 1: Mild bone loss. Undistorted rim

Type 2: Intermediate bone loss. Distorted but intact rim, will support cup.

Type 3: Severe bone loss. Non-supportive rim.

be restored with metal meshes in order to recreate a contained defect. Next, these defects are filled with tightly impacted morselized allograft cancellous bone chips in combination with a cemented new prosthesis. The allograft bone serves as a scaffold; new blood vessels and woven bone can grow into the allograft bone and during this process the allograft bone is resorbed by osteoclasts. The remodelling of newly formed immature bone into its characteristic mature bony structure will lead to a biological repair of the defect [17]. From biopsies taken from the acetabular component of patients who underwent hip revision surgery with bone impaction grafting, it is clear that the allograft bone will be almost completely remodeled and replaced by new bone [18], although this might take several months or even years [19].

BIG for bone loss in hip revision cases has been used with satisfactory results in clinical practice for acetabular revisions since 1979 and for femoral defects in revision surgery



**Figure 1.2** Impactation grafting technique, obtained from Schreurs et al. [23].

- A. Hip with an acetabular defect after removal of the failed cup
- B. The medial wall defect is closed by a metal mesh that can be fixed with screws
- C. The cavity defect is filled layer by layer with bone graft chips
- D. These bone graft chips are impacted
- E. After impactation, the impactors can be removed without collapse of the construction
- F. Cement is injected and pressurized to facilitate cement penetration into the graft
- G. Hip after cup insertion

since 1987 [14, 20-26]. Survival rates between 52% and 94% have been reported up to 28 years after the surgery with BIG [14, 24, 27-32]. BIG is a frequently applied procedure to restore bone stock losses. Lie et al. [13] evaluated hip revision surgeries from 1987 to 2003 in Norway and found that in 29% of all acetabular revisions bone graft is used and in 11% BIG is applied. For femoral revisions these percentages are 28% and 19%, respectively.

This thesis will focus on BIG and how in the future the results of hip revision surgery with BIG could be improved by treatment of the allograft bone chips which are used during impactation grafting.

## **Allograft bone and bone banking**

Autograft bone is the best material to restore bony defects [33]. Autograft bone has a major advantage in that it provides not only a three-dimensional structure of bone (osteoconduction), but also osteoblasts that will form new bone (osteogenesis) [33]. Moreover, autograft bone will trigger the formation of new osteoblasts, theoretically promoting faster integration of the graft (osteo-induction). However, donor site morbidity and limited availability are the major drawbacks in the use of autograft bone in reconstructive surgery [18]. Therefore, bone graft substitutes or allograft bone might be used during orthopedic surgeries for the reconstruction of bone defects. An increasing number of bone substitutes is available on the market. Examples of bone graft substitutes are tricalcium phosphate, calcium sulphate and hydroxyapatite. These substitutes are osteoconductive materials and have the advantages of being totally free of potentially infectious diseases and do not cause an immune-rejection reaction [34]. Contrary, allograft bone might transmit infectious diseases, although this is very rare [33]. Allograft bone is osteoconductive but might also release growth factors which could stimulate some degree of osteo-induction [18, 35]. Allograft bone for bone transplantations has been used for over 130 years; the first known bone transplant in humans has been performed in 1878 [36]. In the 1950s the first tissue bank was founded, the Navy Tissue Bank in Bethesda, Maryland [37]. A system was created in which cadaver donation was performed in an operating room which was dedicated solely to tissue procurement, which increased the availability of allograft tissue. In The Netherlands, a central bone bank was established in 1988 [38]. With increasing amounts of surgical procedures, the demand for allograft bone also increased [36]. After 1980, emphasis was placed on safety and prevention of disease transmission, since it was clear from several cases that allograft bone might transmit blood-borne diseases [36]. Last decades, first American guidelines on donor selection, tissue quarantine and tissue processing were developed [39] followed by the development of European guidelines [40]. With stringent donor selection and improved screening methods, the risk of viral transmission is reduced [33].

For BIG, mostly femoral heads from living donors are used. These femoral heads can be processed or used fresh frozen. Processing includes several methods to clean the allograft and remove at least fat, blood and marrow and wash out immunogenic factors [41]. No research has been done on the differences between these fresh frozen and processed allografts [41]. However, it is clear that rinsing the allograft before use improves the

incorporation of the allograft tissue [42]. Improvement of the incorporation of allograft bone might reduce the risk of failure.

### **Loosening and hip revision surgery**

Nineteen to thirty percent of all failures after revision surgery are caused by loosening of the prosthesis [6, 15, 43, 44]. After hip revision surgery with BIG, remodeling of the allograft bone occurs by a process called creeping substitution. Creeping substitution or “schleichender ersatz” as it was first named by Axhausen in 1907 is an ongoing process of bone resorption and bone deposition in the skeleton throughout life, refreshing the tissue, adapting to mechanical stress or metabolic changes [45]. When allograft or autograft bone tissue is being used, this process also takes place, however the coupling between osteoblast and osteoclast function is less organized. Therefore it might lead to faster resorption in relation to bone deposition. In the case of BIG this may lead to destabilization of the implant. This mechanical weakness might result in loosening of the prosthesis. To optimize the balance between bone resorption and bone formation bisphosphonates might be used. Bisphosphonates are used for a variety of bone diseases in which excessive osteoclast activity is an important feature, including Paget’s disease, bone tumors and, of course, osteoporosis [46]. Bisphosphonates were first synthesized in the 1800s and used as corrosion inhibitors, and in the textile, fertilizer and oil industry as ‘water softeners’ [46]. Their medical uses were not recognized until the 1960s. Fleisch, Russell and co-workers discovered that bisphosphonates have a high affinity for bone mineral. Using bisphosphonates, they were able to prevent calcification of many soft tissues as well as originally calcified tissues as bone and cartilage [47, 48]. In 1969 the first studies of the use of bisphosphonates in humans were published [46, 48]. Bisphosphonates inhibit bone resorption by inducing apoptosis of the osteoclasts [49, 50].

However, systemic administration of bisphosphonates after hip revision arthroplasty with BIG has the disadvantages that the allograft bone will only be treated once it has been revascularised [51]. Furthermore, blocking necrotic bone resorption, as in the case of a bone graft, may require higher local concentrations, which may be difficult to achieve with systemic treatment [52]. Such problems would be solved if the graft could be treated before implantation. Several studies have been performed on the local application of bisphosphonates, however results vary greatly [53-56]. An overview of all studies combining bisphosphonates with allograft bone is presented in **chapter 2** of this thesis. To investigate whether an optimal dose regarding bone resorption and

bone formation after local application of bisphosphonates with allograft bone exists, an animal study was conducted. Moreover, we questioned whether it is possible to stimulate bone formation with the addition of demineralized bone matrix (DBM) to bone chips impregnated with bisphosphonate. DBM is a product of processed allograft bone and contains collagen, proteins and growth factors [57]. Demineralization of bone might facilitate the release of growth factors which could increase the bioactivity of the graft and increase new bone formation and thus the amount of new bone [58, 59] which might be of importance during the early critical period after surgery with BIG. Results of this study are presented in **chapter 3**.

### **Infection and hip revision surgery**

When joint prosthetic surgery started on a larger scale in the 1960s, infection rates between 5 and 10% were reported for hip as well as for knee replacement [60, 61]. In 1964, Sir John Charnley managed to reduce this percentage by reducing the bacterial content of the air by operating inside a filtered-air enclosure [60]. The numbers of infections have further been reduced by improvements in operating techniques, antibiotics, improvements in operating theatre circumstances, stricter pre- and perioperative routines avoiding operating on patients with active infection (i.e. urinary tract infection) and shorter preoperative hospitalization [61]. Nowadays, infections occur in approximately 0.5 to 3% of all primary THAs and after revision THA, these percentages are higher and range from 4 to 6% [4, 15, 43, 44].

Infection is one of the most common causes of failure after a hip revision surgery, and accounts for 12–30% of all failures [6, 13, 15, 43, 44]. Infection is a potentially devastating complication; patients may require further surgery, additional nursing care and in extreme cases it is followed by the death of the patient. Moreover, it might result in a reduced quality of life and greater physical limitations [62, 63]. Hospital stay increases greatly and some patients are hospitalized for months. Furthermore, the costs of hospitalisation of an infected patient are about 2.5 times higher than the costs of hospitalisation of an uninfected patient (results obtained from RdGG hospital, Delft, The Netherlands, 2012).

Reducing the risk of infection is a major challenge that deserves continued attention. It is important to understand etiology and risk factors for infection to be able to prevent and reduce infection rates. Periprosthetic joint infections occur rarely and risk factors for infection after total joint arthroplasty remain subject of debate [64]. However, it can

be stated that the etiology of infection is multifactorial and can be divided in three major areas: the surgical technique, the surgical environment and the patient [65].

### **The surgical technique**

The use of allograft bone chips for BIG introduces a potential source of infection. In most cases, the allograft bone which is used for BIG, is prepared in the operating theatre during surgery just prior to use. The preparation of bone chips in the operation room takes about ten minutes, it necessitates the use of special instrument such as a bone mill and due to the limited area in a down flow plenum system, an enclosed space inside the operating theatre with laminar air flow, the preparation of bone chips often takes place outside the plenum. However, the processing of these femoral heads can also be done in the laboratory of a bone bank. In that case the femoral heads are prepared in a top-class level clean room with optimal controlled environmental conditions and no surgery time is needed for preparation. Therefore, in **chapter 4** we investigated the potential benefit in terms of lower contamination rates of the use of pre-processed bone chips when compared to bone chips prepared intra-operatively.

Relatively small numbers of bacteria of low virulence are able to establish infection in the presence of the surgical implant [66-69]. These infections are usually treated by administering high dose antibiotics systematically for prolonged periods of time. The effect of systemic administrated antibiotics as a prophylaxis against infection, has been studied by Lidwell et al. [70]. A positive effect with regard to infection has been shown in that study. However, the surgery creates a vascular compromised wound bed where local circulation is disrupted. If infection arises, poorly vascularized tissue is less likely to sustain adequate antibiotics levels when antibiotics are administered systemically [71]. In addition, the formation of a biofilm on the surface of the implant renders systemic antibiotics less effective [69]. As a prophylaxis against these infections, bone cements containing antibiotics were developed. These cements may serve as a drug delivery system as they make it possible to achieve higher local drug concentrations. However, controversy exists on the efficacy of the antibiotic-containing cements [72]. Probably 90% of the antibiotics contained in the cement is never released [73]. Only when cracks are formed in the cement layer, a small sub-inhibitory amount of antibiotics will be released into the surrounding tissue. This release can continue for years, potentially inducing resistance [73].

Several studies have shown that the allograft bone, used for BIG, can act as a carrier for antibiotics, either by impregnating the bone grafts with various antibiotic solutions [74-78], or by mixing them with antibiotic powders [79, 80]. These studies showed that bone impregnated with antibiotics can be used effectively as prophylaxis against infections. However, not much is known about the local release of the antibiotics from the allograft bone. Therefore, in **chapter 5** of this thesis, we investigated whether it was possible to develop a standardized bone bank product in which the amount of antibiotics present on the bone chips, and therefore the amount of antibiotics released locally from the bone, are known. In addition, we investigated if storage of antibiotics and antibiotic-loaded bone grafts at different temperatures affects their activity.

In **chapter 3**, a study is presented in which we investigated whether local use of antibiotics has influence on bone formation and graft remodeling in a goat model.

## **The surgical environment**

Since Charnley managed to reduce infection rates after total joint arthroplasties by operating inside a filtered-air enclosure, several improvements in surgical environment have been done. Enhancing air quality by reducing airborne contamination has been shown to be of great importance, especially in relation to implant surgery. An important development is the introduction of laminar air flow (LAF) at the operating room [81]. Lidwell et al. [70] concluded in their landmark study that there is a strong relation between the level of bacterial air contamination and the prevalence of deep surgical site infection. Prosthesis infection may occur post-operatively, but is often caused by bacterial contamination intra-operatively [82]. Transfer of bacteria from the skin of the patient or theatre personnel through instruments and other materials to the wound area, might result in intra-operative contamination [83] and as much as 70% of all air-borne bacteria reach the wound via hands of the surgical personnel or by instruments used [84, 85]. Several studies have been performed on the amounts of colony forming units (CFUs) at the surgical site, airflow in the operating room, discipline in the operating room and particle counts [82, 86-90] all with different results. Although these results are contradictory, it has been suggested that levels of CFU should be maintained at  $< 10\text{CFU}/\text{m}^3$  during implant surgery, and that clinical benefits can be expected by reducing it to  $1\text{CFU}/\text{m}^3$  [91].

**Chapter 6** focused on air quality and the effect of door-openings on the number of CFUs, measured during hip revision arthroplasty, classified as being a high risk operation. It was



hypothesized that a reduced frequency of door-openings will lead to reduced numbers of CFUs during surgery.

## **The patient**

Although several improvements such as the use of prophylactic antibiotics and laminar airflow in the operating room contributed to reduce infection rates after total joint arthroplasties, the risk of infection has not been eliminated. Contrary, infection rates in the modern hospital centers are higher than compared to that in the 1970s, since nowadays, more elderly people and patients with preexisting co-morbidities are undergoing a total joint arthroplasty [92]. The patient-related factors which might have an influence on the development of infection are very important, however are outside the scope of this thesis and therefore not discussed here.

## **Imaging of bone remodeling**

Radiographs are used to evaluate patients after hip revision surgery with BIG [14, 24, 30, 31]. Radiolucent lines as well as position of the prosthesis are identified to detect possible loosening. However, radiographs do not provide information on the process of bone remodeling after BIG and the appearance of the graft is difficult to interpret radiologically [93]. To gain more insight in this process, biopsies or autopsies from the graft material have been evaluated histologically [94, 95]. Results showed that bone remodeling is slow and that bony healing after hip revision surgery with BIG may be less predictable compared to primary hip arthroplasty. Ullmark et al. [96] used positron emission tomography (PET) to study bone metabolism and bone formation in allografts surrounding the femur component in revision surgery. They concluded that bone metabolism was significantly reduced at 6 years after the surgery, when compared to the elevated activity during the first year postoperatively, but also when compared to the contra-lateral side.

To understand bone remodeling around primary prosthetic hip implants, several studies used Dual-Energy X-ray Absorptiometry (DEXA) [97-105]. DEXA is a relatively cheap method with low radiation burden. However, less is known on DEXA and hip revision arthroplasty with bone impaction grafting. Laursen et al. [106] studied experimental defects around acetabular components in human post mortem pelvis specimens. They concluded that DEXA scanning provides a sensitive measure of changes in bone mineral content (BMC) around cementless hemispherical metal-backed cups.

Since early visualization of increased bone resorption might be of importance for early diagnosis of bone loss, DEXA might be a tool for quantification of changes in bone content and bone remodeling. Therefore, in **chapter 7** of this thesis DEXA for bone impaction grafting and bone remodeling after hip revision surgery was evaluated.

## REFERENCES

1. Conditions NCCfC: **Osteoarthritis: national clinical guideline for care and management in adults**. 2011/02/04 edn. London: Royal College of Physicians; 2008.
2. Verhaar JAN, van Mourik JBA: **Orthopedie**, vol. 2. Houten: Bohn Stafleu van Loghum; 2008.
3. Poos MJJC (RIVM) GAR, Uiters E (RIVM), Zantinge EM (RIVM): **Hoe vaak komt artrose voor en hoeveel mensen sterven eraan?** In: *Volksgezondheid Toekomst Verkenning, Nationaal Kompas Volksgezondheid*. Bilthoven:: RIVM; 2009.
4. Pivec R, Johnson AJ, Mears SC, Mont MA: **Hip arthroplasty**. *Lancet* 2012, **380**(9855):1768-1777.
5. Learmonth ID, Young C, Rorabeck C: **The operation of the century: total hip replacement**. *Lancet* 2007, **370**(9597):1508-1519.
6. Bozic KJ, Kurtz SM, Lau E, Ong K, Vail TP, Berry DJ: **The epidemiology of revision total hip arthroplasty in the United States**. *J Bone Joint Surg Am* 2009, **91**(1):128-133.
7. Santavirta S, Konttinen YT, Bergroth V, Eskola A, Tallroth K, Lindholm TS: **Aggressive granulomatous lesions associated with hip arthroplasty. Immunopathological studies**. *J Bone Joint Surg Am* 1990, **72**(2):252-258.
8. Pizzoferrato A, Ciapetti G, Stea S, Toni A: **Cellular events in the mechanisms of prosthesis loosening**. *Clin Mater* 1991, **7**(1):51-81.
9. Holt G, Murnaghan C, Reilly J, Meek RM: **The biology of aseptic osteolysis**. *Clin Orthop Relat Res* 2007, **460**:240-252.
10. Paprosky WG, Bradford MS, Younger TI: **Classification of bone defects in failed prostheses**. *Chir Organi Mov* 1994, **79**(4):285-291.
11. NOV: **LROI-Rapportage 2007-2011. Registreren voor een betere zorg. Eerste jaarregistratie uit de Landelijke Registratie Orthopedische Implantaten 2007-2011**. In.; 2012.
12. Best JT: **Revision total hip and total knee arthroplasty**. *Orthop Nurs* 2005, **24**(3):174-179; quiz 180-171.
13. Lie SA, Havelin LI, Furnes ON, Engesaeter LB, Vollset SE: **Failure rates for 4762 revision total hip arthroplasties in the Norwegian Arthroplasty Register**. *J Bone Joint Surg Br* 2004, **86**(4):504-509.
14. Schreurs BW, Arts JJ, Verdonschot N, Buma P, Slooff TJ, Gardeniers JW: **Femoral component revision with use of impaction bone-grafting and a cemented polished stem. Surgical technique**. *J Bone Joint Surg Am* 2006, **88 Suppl 1 Pt 2**:259-274.

15. Lamberton TD, Kenny PJ, Whitehouse SL, Timperley AJ, Gie GA: **Femoral impaction grafting in revision total hip arthroplasty: a follow-up of 540 hips.** *J Arthroplasty* 2011, **26**(8):1154-1160.
16. Retpen JB, Varmarken JE, Jensen JS: **Survivorship analysis of failure pattern after revision total hip arthroplasty.** *J Arthroplasty* 1989, **4**(4):311-317.
17. Schreurs BW, Slooff TJ, Buma P, Gardeniers JW, Huiskes R: **Acetabular reconstruction with impacted morsellised cancellous bone graft and cement. A 10- to 15-year follow-up of 60 revision arthroplasties.** *J Bone Joint Surg Br* 1998, **80**(3):391-395.
18. van der Donk S, Buma P, Slooff TJ, Gardeniers JW, Schreurs BW: **Incorporation of morselized bone grafts: a study of 24 acetabular biopsy specimens.** *Clin Orthop Relat Res* 2002(396):131-141.
19. Linder L: **Cancellous impaction grafting in the human femur: histological and radiographic observations in 6 autopsy femurs and 8 biopsies.** *Acta Orthop Scand* 2000, **71**(6):543-552.
20. Schreurs BW, Bolder SB, Gardeniers JW, Verdonschot N, Slooff TJ, Veth RP: **Acetabular revision with impacted morsellised cancellous bone grafting and a cemented cup. A 15- to 20-year follow-up.** *The Journal of bone and joint surgery* 2004, **86**(4):492-497.
21. Schreurs BW, Thien TM, de Waal Malefijt MC, Buma P, Veth RP, Slooff TJ: **Acetabular revision with impacted morselized cancellous bone graft and a cemented cup in patients with rheumatoid arthritis: three to fourteen-year follow-up.** *J Bone Joint Surg Am* 2003, **85-A**(4):647-652.
22. Schreurs BW, Luttjeboer J, Thien TM, de Waal Malefijt MC, Buma P, Veth RP, Slooff TJ: **Acetabular revision with impacted morselized cancellous bone graft and a cemented cup in patients with rheumatoid arthritis. A concise follow-up, at eight to nineteen years, of a previous report.** *J Bone Joint Surg Am* 2009, **91**(3):646-651.
23. Schreurs BW, Slooff TJ, Gardeniers JW, Buma P: **Acetabular reconstruction with bone impaction grafting and a cemented cup: 20 years' experience.** *Clin Orthop Relat Res* 2001(393):202-215.
24. Schreurs BW, Arts JJ, Verdonschot N, Buma P, Slooff TJ, Gardeniers JW: **Femoral component revision with use of impaction bone-grafting and a cemented polished stem.** *J Bone Joint Surg Am* 2005, **87**(11):2499-2507.
25. Slooff TJ, Huiskes R, van Horn J, Lemmens AJ: **Bone grafting in total hip replacement for acetabular protrusion.** *Acta Orthop Scand* 1984, **55**(6):593-596.
26. Gie GA, Linder L, Ling RS, Simon JP, Slooff TJ, Timperley AJ: **Impacted cancellous allografts and cement for revision total hip arthroplasty.** *J Bone Joint Surg Br* 1993, **75**(1):14-21.
27. Schreurs BW, Gardeniers JW, Slooff TJ: **Acetabular reconstruction with bone impaction grafting: 20 years of experience.** *Instr Course Lect* 2001, **50**:221-228.
28. van Egmond N, De Kam DC, Gardeniers JW, Schreurs BW: **Revisions of extensive acetabular defects with impaction grafting and a cement cup.** *Clin Orthop Relat Res* 2011, **469**(2):562-573.

29. te Stroet MA, Gardeniers JW, Verdonschot N, Rijnen WH, Slooff TJ, Schreurs BW: **Femoral component revision with use of impaction bone-grafting and a cemented polished stem: a concise follow-up, at fifteen to twenty years, of a previous report.** *J Bone Joint Surg Am* 2012, **94**(23):e1731-1734.
30. Busch VJ, Gardeniers JW, Verdonschot N, Slooff TJ, Schreurs BW: **Acetabular reconstruction with impaction bone-grafting and a cemented cup in patients younger than fifty years old: a concise follow-up, at twenty to twenty-eight years, of a previous report.** *J Bone Joint Surg Am* 2011, **93**(4):367-371.
31. Garvin KL, Konigsberg BS, Ommen ND, Lyden ER: **What is the Long-term Survival of Impaction Allografting of the Femur?** *Clin Orthop Relat Res* 2013.
32. Ten Have BL, Brouwer RW, van Biezen FC, Verhaar JA: **Femoral revision surgery with impaction bone grafting: 31 hips followed prospectively for ten to 15 years.** *J Bone Joint Surg Br* 2012, **94**(5):615-618.
33. Delloye C, Cornu O, Druetz V, Barbier O: **Bone allografts: What they can offer and what they cannot.** *J Bone Joint Surg Br* 2007, **89**(5):574-579.
34. Kurien T, Pearson RG, Scammell BE: **Bone graft substitutes currently available in orthopaedic practice: The evidence for their use.** *Bone Joint J* 2013, **95-B**(5):583-597.
35. de la Piedra C, Vicario C, de Acuna LR, Garcia-Moreno C, Traba ML, Arlandis S, Marco F, Lopez-Duran L: **Osteoinductive effect of bone bank allografts on human osteoblasts in culture.** *J Orthop Res* 2008, **26**(2):200-207.
36. Tomford WW: **Bone allografts: past, present and future.** *Cell Tissue Bank* 2000, **1**(2):105-109.
37. Hyatt GW: **Fundamentals in the use and preservation of homogenous bone.** *U S Armed Forces Med J* 1950, **1**(8):841-852.
38. Deijkers RL, Vehmeyer SB, Veen MR, Persijn GG, Bloem RM: **[5-year experience with a central bone bank].** *Ned Tijdschr Geneeskde* 1995, **139**(12):622-626.
39. Linden JV, Favreau TJ: **Professional standards in cell and tissue processing.** *Cell Transplant* 1995, **4**(5):441-446.
40. **Directive 2004/23/EC of the European parliament and of the council of 31 March 2004 on setting standards of quality and safety for the donation, procurement, testing, processing, preservation, storage and distribution of human tissues and cells.** In: *Official Journal of Eur Union*. Edited by Union E, vol. L102; 2004: 48-58.
41. Board TN, Brunskill S, Doree C, Hyde C, Kay PR, Meek RD, Webster R, Galea G: **Processed versus fresh frozen bone for impaction bone grafting in revision hip arthroplasty.** *Cochrane Database Syst Rev* 2009(4):CD006351.
42. van der Donk S, Weernink T, Buma P, Aspenberg P, Slooff TJ, Schreurs BW: **Rinsing morselized allografts improves bone and tissue ingrowth.** *Clin Orthop Relat Res* 2003(408):302-310.
43. Springer BD, Fehring TK, Griffin WL, Odum SM, Masonis JL: **Why revision total hip arthroplasty fails.** *Clin Orthop Relat Res* 2009, **467**(1):166-173.

44. Jafari SM, Coyle C, Mortazavi SM, Sharkey PF, Parvizi J: **Revision hip arthroplasty: infection is the most common cause of failure.** *Clin Orthop Relat Res* 2010, **468**(8):2046-2051.
45. Axhausen: **Histologishe untersuch ungen uber knochentransplantation am menschen.** *KDeutsche Ztschr F chir Leipz* 1907, **93**:388-392.
46. Russell RG: **Bisphosphonates: the first 40 years.** *Bone* 2011, **49**(1):2-19.
47. Fleisch HA, Russell RG, Bisaz S, Muhlbauer RC, Williams DA: **The inhibitory effect of phosphonates on the formation of calcium phosphate crystals in vitro and on aortic and kidney calcification in vivo.** *Eur J Clin Invest* 1970, **1**(1):12-18.
48. Fleisch H: **Diphosphonates: history and mechanisms of action.** *Metab Bone Dis Relat Res* 1981, **3**(4-5):279-287.
49. Russell RG, Rogers MJ, Frith JC, Luckman SP, Coxon FP, Benford HL, Croucher PI, Shipman C, Fleisch HA: **The pharmacology of bisphosphonates and new insights into their mechanisms of action.** *J Bone Miner Res* 1999, **14 Suppl 2**:53-65.
50. Fleisch H: **Bisphosphonates: mechanisms of action.** *Endocr Rev* 1998, **19**(1):80-100.
51. Tagil M, Aspenberg P, Astrand J: **Systemic zoledronate precoating of a bone graft reduces bone resorption during remodeling.** *Acta Orthop* 2006, **77**(1):23-26.
52. Kesteris U, Aspenberg P: **Rinsing morcellised bone grafts with bisphosphonate solution prevents their resorption. A prospective randomised double-blinded study.** *J Bone Joint Surg Br* 2006, **88**(8):993-996.
53. Baas J, Elmengaard B, Jensen TB, Jakobsen T, Andersen NT, Soballe K: **The effect of pretreating morselized allograft bone with rhBMP-2 and/or pamidronate on the fixation of porous Ti and HA-coated implants.** *Biomaterials* 2008, **29**(19):2915-2922.
54. Tagil M, Astrand J, Westman L, Aspenberg P: **Alendronate prevents collapse in mechanically loaded osteochondral grafts: a bone chamber study in rats.** *Acta Orthop Scand* 2004, **75**(6):756-761.
55. Jeppsson C, Astrand J, Tagil M, Aspenberg P: **A combination of bisphosphonate and BMP additives in impacted bone allografts.** *Acta Orthop Scand* 2003, **74**(4):483-489.
56. Jakobsen T, Baas J, Bechtold JE, Elmengaard B, Soballe K: **Soaking morselized allograft in bisphosphonate can impair implant fixation.** *Clin Orthop Relat Res* 2007, **463**:195-201.
57. Watson JT: **Overview of biologics.** *J Orthop Trauma* 2005, **19**(10 Suppl):S14-16.
58. Wildemann B, Kadow-Romacker A, Haas NP, Schmidmaier G: **Quantification of various growth factors in different demineralized bone matrix preparations.** *J Biomed Mater Res A* 2007, **81**(2):437-442.
59. Shih HN, Shih LY, Sung TH, Chang YC: **Restoration of bone defect and enhancement of bone ingrowth using partially demineralized bone matrix and marrow stromal cells.** *J Orthop Res* 2005, **23**(6):1293-1299.
60. Charnley J: **A Clean-Air Operating Enclosure.** *Br J Surg* 1964, **51**:202-205.
61. Lidgren L: **Joint prosthetic infections: a success story.** *Acta Orthop Scand* 2001, **72**(6):553-556.

62. Whitehouse JD, Friedman ND, Kirkland KB, Richardson WJ, Sexton DJ: **The impact of surgical-site infections following orthopedic surgery at a community hospital and a university hospital: adverse quality of life, excess length of stay, and extra cost.** *Infect Control Hosp Epidemiol* 2002, **23**(4):183-189.
63. Plowman R: **The socioeconomic burden of hospital acquired infection.** *Euro Surveill* 2000, **5**(4):49-50.
64. Ong KL, Kurtz SM, Lau E, Bozic KJ, Berry DJ, Parvizi J: **Prosthetic joint infection risk after total hip arthroplasty in the Medicare population.** *J Arthroplasty* 2009, **24**(6 Suppl):105-109.
65. Andersson AE, Bergh I, Karlsson J, Nilsson K: **Patients' experiences of acquiring a deep surgical site infection: an interview study.** *Am J Infect Control* 2010, **38**(9):711-717.
66. Mahomed NN, Barrett JA, Katz JN, Phillips CB, Losina E, Lew RA, Guadagnoli E, Harris WH, Poss R, Baron JA: **Rates and outcomes of primary and revision total hip replacement in the United States medicare population.** *J Bone Joint Surg Am* 2003, **85-A**(1):27-32.
67. Zhan C, Kaczmarek R, Loyo-Berrios N, Sangl J, Bright RA: **Incidence and short-term outcomes of primary and revision hip replacement in the United States.** *J Bone Joint Surg Am* 2007, **89**(3):526-533.
68. Ridgeway S, Wilson J, Charlet A, Kafatos G, Pearson A, Coello R: **Infection of the surgical site after arthroplasty of the hip.** *J Bone Joint Surg Br* 2005, **87**(6):844-850.
69. Gristina AG, Costerton JW: **Bacterial adherence to biomaterials and tissue. The significance of its role in clinical sepsis.** *J Bone Joint Surg Am* 1985, **67**(2):264-273.
70. Lidwell OM, Lowbury EJ, Whyte W, Blowers R, Stanley SJ, Lowe D: **Effect of ultraclean air in operating rooms on deep sepsis in the joint after total hip or knee replacement: a randomised study.** *Br Med J (Clin Res Ed)* 1982, **285**(6334):10-14.
71. Isefuku S, Joyner CJ, Simpson AH: **Gentamicin may have an adverse effect on osteogenesis.** *Journal of orthopaedic trauma* 2003, **17**(3):212-216.
72. van de Belt H, Neut D, Schenk W, van Horn JR, van der Mei HC, Busscher HJ: **Infection of orthopedic implants and the use of antibiotic-loaded bone cements. A review.** *Acta Orthop Scand* 2001, **72**(6):557-571.
73. Winkler H, Kaudela K, Stoiber A, Menschik F: **Bone grafts impregnated with antibiotics as a tool for treating infected implants in orthopedic surgery - one stage revision results.** *Cell and tissue banking* 2006, **7**(4):319-323.
74. Witso E, Persen L, Benum P, Bergh K: **Release of netilmicin and vancomycin from cancellous bone.** *Acta Orthop Scand* 2002, **73**(2):199-205.
75. Witso E, Persen L, Benum P, Aamodt A, Husby OS, Bergh K: **High local concentrations without systemic adverse effects after impaction of netilmicin-impregnated bone.** *Acta Orthop Scand* 2004, **75**(3):339-346.
76. Winkler H, Janata O, Berger C, Wein W, Georgopoulos A: **In vitro release of vancomycin and tobramycin from impregnated human and bovine bone grafts.** *The Journal of antimicrobial chemotherapy* 2000, **46**(3):423-428.
77. Witso E, Persen L, Loseth K, Benum P, Bergh K: **Cancellous bone as an antibiotic carrier.** *Acta Orthop Scand* 2000, **71**(1):80-84.

78. Witso E, Persen L, Benum P, Bergh K: **Cortical allograft as a vehicle for antibiotic delivery.** *Acta Orthop* 2005, **76**(4):481-486.
79. Buttaro MA, Gimenez MI, Greco G, Barcan L, Piccaluga F: **High active local levels of vancomycin without nephrotoxicity released from impacted bone allografts in 20 revision hip arthroplasties.** *Acta Orthop* 2005, **76**(3):336-340.
80. Buttaro MA, Gonzalez Della Valle AM, Pineiro L, Mocetti E, Morandi AA, Piccaluga F: **Incorporation of vancomycin-supplemented bone incorporation of vancomycin-supplemented bone allografts: radiographical, histopathological and immunohistochemical study in pigs.** *Acta Orthop Scand* 2003, **74**(5):505-513.
81. Evans RP: **Current concepts for clean air and total joint arthroplasty: laminar airflow and ultraviolet radiation: a systematic review.** *Clin Orthop Relat Res* 2011, **469**(4):945-953.
82. Knobben BA, Engelsma Y, Neut D, van der Mei HC, Busscher HJ, van Horn JR: **Intraoperative contamination influences wound discharge and periprosthetic infection.** *Clin Orthop Relat Res* 2006, **452**:236-241.
83. Davis N, Curry A, Gambhir AK, Panigrahi H, Walker CR, Wilkins EG, Worsley MA, Kay PR: **Intraoperative bacterial contamination in operations for joint replacement.** *J Bone Joint Surg Br* 1999, **81**(5):886-889.
84. Whyte W, Hodgson R, Tinkler J: **The importance of airborne bacterial contamination of wounds.** *J Hosp Infect* 1982, **3**(2):123-135.
85. Shaw JA, Bordner MA, Hamory BH: **Efficacy of the Steri-Shield filtered exhaust helmet in limiting bacterial counts in the operating room during total joint arthroplasty.** *J Arthroplasty* 1996, **11**(4):469-473.
86. Verkkala K, Eklund A, Ojajarvi J, Tiittanen L, Hoborn J, Makela P: **The conventionally ventilated operating theatre and air contamination control during cardiac surgery-bacteriological and particulate matter control garment options for low level contamination.** *Eur J Cardiothorac Surg* 1998, **14**(2):206-210.
87. Der Tavitian J, Ong SM, Taub NA, Taylor GJ: **Body-exhaust suit versus occlusive clothing. A randomised, prospective trial using air and wound bacterial counts.** *J Bone Joint Surg Br* 2003, **85**(4):490-494.
88. Friberg B, Friberg S, Burman LG: **Inconsistent correlation between aerobic bacterial surface and air counts in operating rooms with ultra clean laminar air flows: proposal of a new bacteriological standard for surface contamination.** *J Hosp Infect* 1999, **42**(4):287-293.
89. Pasquarella C, Pitzurra O, Herren T, Poletti L, Savino A: **Lack of influence of body exhaust gowns on aerobic bacterial surface counts in a mixed-ventilation operating theatre. A study of 62 hip arthroplasties.** *J Hosp Infect* 2003, **54**(1):2-9.
90. Stocks GW, Self SD, Thompson B, Adame XA, O'Connor DP: **Predicting bacterial populations based on airborne particulates: a study performed in nonlaminar flow operating rooms during joint arthroplasty surgery.** *Am J Infect Control*, **38**(3):199-204.
91. Hoffman PN, Williams J, Stacey A, Bennett AM, Ridgway GL, Dobson C, Fraser I, Humphreys H: **Microbiological commissioning and monitoring of operating theatre suites.** *J Hosp Infect* 2002, **52**(1):1-28.



92. Yinnon AM, Wiener-Well Y, Jerassy Z, Dor M, Freund R, Mazouz B, Lupyan T, Shapira S, Attias D, Assous MV *et al*: **Improving implementation of infection control guidelines to reduce nosocomial infection rates: pioneering the report card.** *J Hosp Infect* 2012, **81**(3):169-176.
93. Buttaro MA, Costantini J, Comba F, Piccaluga F: **The use of femoral struts and impacted cancellous bone allograft in patients with severe femoral bone loss who undergo revision total hip replacement: a three- to nine-year follow-up.** *J Bone Joint Surg Br* 2012, **94**(2):167-172.
94. Buma P, Lamerigts N, Schreurs BW, Gardeniers J, Versleyen D, Slooff TJ: **Impacted graft incorporation after cemented acetabular revision. Histological evaluation in 8 patients.** *Acta Orthop Scand* 1996, **67**(6):536-540.
95. Ullmark G, Obrant KJ: **Histology of impacted bone-graft incorporation.** *J Arthroplasty* 2002, **17**(2):150-157.
96. Ullmark G, Sorensen J, Langstrom B, Nilsson O: **Bone regeneration 6 years after impaction bone grafting: a PET analysis.** *Acta Orthop* 2007, **78**(2):201-205.
97. Venesmaa PK, Kroger HP, Jurvelin JS, Miettinen HJ, Suomalainen OT, Alhava EM: **Periprosthetic bone loss after cemented total hip arthroplasty: a prospective 5-year dual energy radiographic absorptiometry study of 15 patients.** *Acta Orthop Scand* 2003, **74**(1):31-36.
98. Wilkinson JM, Peel NE, Elson RA, Stockley I, Eastell R: **Measuring bone mineral density of the pelvis and proximal femur after total hip arthroplasty.** *J Bone Joint Surg Br* 2001, **83**(2):283-288.
99. Kroger H, Miettinen H, Arnala I, Koski E, Rushton N, Suomalainen O: **Evaluation of periprosthetic bone using dual-energy x-ray absorptiometry: precision of the method and effect of operation on bone mineral density.** *J Bone Miner Res* 1996, **11**(10):1526-1530.
100. Damborg F, Nissen N, Jorgensen HR, Abrahamsen B, Brixen K: **Changes in bone mineral density (BMD) around the cemented Exeter stem: a prospective study in 18 women with 5 years follow-up.** *Acta Orthop* 2008, **79**(4):494-498.
101. Martini F, Leberz C, Mayer F, Leichte U, Kremling E, Sell S: **Precision of the measurements of periprosthetic bone mineral density in hips with a custom-made femoral stem.** *J Bone Joint Surg Br* 2000, **82**(7):1065-1071.
102. Okano T, Hagino H, Otsuka T, Teshima R, Yamamoto K, Hirano Y, Nakamura K: **Measurement of periprosthetic bone mineral density by dual-energy x-ray absorptiometry is useful for estimating fixation between the bone and the prosthesis in an early stage.** *J Arthroplasty* 2002, **17**(1):49-55.
103. Venesmaa PK, Kroger HP, Miettinen HJ, Jurvelin JS, Suomalainen OT, Alhava EM: **Monitoring of periprosthetic BMD after uncemented total hip arthroplasty with dual-energy X-ray absorptiometry--a 3-year follow-up study.** *J Bone Miner Res* 2001, **16**(6):1056-1061.



104. Kilgus DJ, Shimaoka EE, Tipton JS, Eberle RW: **Dual-energy X-ray absorptiometry measurement of bone mineral density around porous-coated cementless femoral implants. Methods and preliminary results.** *J Bone Joint Surg Br* 1993, 75(2):279-287.
105. Smart RC, Barbagallo S, Slater GL, Kuo RS, Butler SP, Drummond RP, Sekel R: **Measurement of periprosthetic bone density in hip arthroplasty using dual-energy x-ray absorptiometry. Reproducibility of measurements.** *J Arthroplasty* 1996, 11(4):445-452.
106. Laursen MB, Nielsen PT, Soballe K: **Detection of bony defects around cementless acetabular components in total hip arthroplasty: a DEXA study on 10 human cadavers.** *Acta Orthop* 2006, 77(2):209-217.
107. Weeden SH, Paprosky WG: **Porous-ingrowth revision acetabular implants secured with peripheral screws. A minimum twelve-year follow-up.** *J Bone Joint Surg Am* 2006, 88(6):1266-1271.



## CHAPTER 2

# COMBINING BISPHOSPHONATES WITH ALLOGRAFT BONE FOR IMPLANT FIXATION: A REVIEW

Nina M.C. Mathijssen, Pieter Buma, Gerjon Hannink  
Accepted Cell and Tissue Banking

## **ABSTRACT**

The aim of this review was to discuss the current state of research of combining bisphosphonates with allograft bone for implant fixation. The allograft bone can only be reached by the bisphosphonate once it has been revascularized. However, this can be circumvented by local administration of bisphosphonates. Several animal studies showed that local application of bisphosphonates might protect the graft from resorption. There seems to be an optimum concentration for local application, however, this optimum varies for all different bisphosphonates. It can be concluded that local administration of bisphosphonates might play an important role in improving stability after surgery in which a prosthesis is combined with allograft bone to restore bony defects, however caution should be taken when extrapolating results of animal research to the human clinical situation. More research is needed to study the effect of local bisphosphonate use in humans and to study possible side effects.

## Background

Bisphosphonates are used for a variety of bone diseases in which excessive osteoclast activity is an important feature, including Paget's disease, bone tumors and, of course, osteoporosis [1]. Their ability to reduce the risk of fractures has saved thousands of people from becoming fracture patients. More recently, suggestions have been made on the use of bisphosphonates in fracture repair and implant fixation [2]. As research on the use of bisphosphonates has mainly focused on osteoporosis, their effects on repair processes have long been disregarded. Osteoporosis is due to an imbalance in bone remodeling. This remodeling is different from the repair processes that occur after fracture or bone surgery [3]. In bone remodeling, osteoclasts and osteoblasts work closely together. Their activities are coupled, i.e. a decrease in bone resorption due to bisphosphonates leads to a reduction in bone formation to a similar degree. Therefore, it was thought that bisphosphonates would only slow down bone repair. However, in bone repair, osteoblasts can work independently. Osteoblasts are metabolically demanding cells with high levels of energy consumption, requiring an adequate blood supply, while there is no relation between osteoclasts and vascularization [4]. Therefore, a trend towards an increase in bone resorption can be expected when vascularization is absent, after surgery. A reduction in osteoclastic activity might therefore shift the balance between formation and resorption towards increased net bone formation [2].

Bisphosphonates bind to bone mineral and are taken up by osteoclasts when these cells resorb bone, which subsequently inactivates them. Bisphosphonates can be divided into two groups with different modes of action. The first group contains bisphosphonates, such as etidronate and clodronate, that closely resemble pyrophosphate. The bisphosphonate can be metabolically incorporated into nonhydrolyzable analogs of ATP that may inhibit ATP-dependent intracellular enzymes in the osteoclast, subsequently resulting in apoptosis of the osteoclast. The more potent, nitrogen-containing bisphosphonates, such as zoledronate, alendronate and ibandronate, inhibit the mevalonate pathway. The inhibition of protein prenylation results in the loss of osteoclast activity and induction of apoptosis. [5, 6].

The initial fixation of joint prostheses appears to be crucial for long-term success. The surfaces of joint replacements are mostly adjacent to cancellous bone. Due to the operative trauma or circulatory disturbance, osteocytes next to an implant will die. Bisphosphonates may inhibit resorption of the bone next to the prosthesis, which can be nothing but necrotic and prone to resorption. Another possibility is that the response to the trauma

gets a more positive balance between bone formation and resorption [1, 7]. An overview of literature on this subject has been written by Aspenberg [2]. It was concluded that, although antiresorptive, bisphosphonates may increase the amount of bone adjacent to an implant, leading to better implant fixation. This has already been shown in several clinical studies, however, should be further evaluated [8, 9].

Allograft bone is often used in reconstruction of (large) bone defects around failed implants. Bone impaction grafting with allograft bone is an example of the use of allograft bone in reconstructive surgery. It has been used in clinical practice since 1979 for acetabular reconstructions and since 1987 for femoral reconstructions with satisfying clinical results [10, 11]. With the bone impaction grafting technique, bone defects in acetabulum and femur are restored with metal meshes. Thereafter, the defect is filled with tightly impacted morselized cancellous bone chips and a cemented prosthesis is placed. The allograft bone serves as a scaffold and the short-term success of revision arthroplasty with impaction grafting is related to the initial stability of the construct. The allograft bone is resorbed by osteoclasts and new bone, formed by osteoblasts, can grow into the allograft. The remodelling of newly formed bone into its characteristic structure will lead to the biological repair of the defect following surgery.

Bisphosphonates might also improve implant fixation when combined with allografts, as the same principle appears to apply to allograft bone, which is in fact necrotic bone next to the prosthesis. To improve mechanical stability and to prevent migration of the implant after surgery, bisphosphonates might be administered either systemically or locally. The aim of this review was to discuss the current state of research of combining bisphosphonates with allograft bone for implant fixation.

### **Systemic administration of bisphosphonates in combination with allografts**

Several studies have been performed on the systemic administration of bisphosphonates after primary arthroplasty [12-18]. It can be concluded from these studies that bisphosphonates reduce periprosthetic bone loss, increase the amount of peri-implant bone and decrease micromovements at the bone-implant interface after primary implant arthroplasty, however, long-term follow-up is not available. Systemic administration of bisphosphonates in combination with allograft bone has been less studied. The effect of systemic administration of zoledronate on the resorption of allograft bone was studied

using bone chambers in rats [19]. Higher amounts of both allograft bone as well as newly formed bone were found in the bisphosphonate group when compared to controls. It was concluded that zoledronate can be used to decrease bone resorption of graft bone as well as increase new bone formation during remodeling.

Long-lasting use of bisphosphonates might be harmful. One of the problems associated with long-term use of bisphosphonates is the development of microcracks, which might be promoted through excessive mineralization [20]. Another problem associated with systemic bisphosphonate treatment is osteonecrosis of the jaw. It was suggested that the incidence of osteonecrosis of the jaw is higher in zoledronic acid treatment than when other bisphosphonates are used. [21]. No reports of osteonecrosis of the jaw or of the development of microcracks have been published after systemic administration of a bisphosphonate after primary arthroplasty, nor when it is used systemically in combination with allograft bone in animal studies.

However, since the application of bisphosphonates in combination with allograft bone is relatively new, problems associated with the use of bisphosphonates known from other applications should be borne in mind.

Systemic administrated bisphosphonates only reach vascularized bone and the necrotic, allograft bone can only be reached by the bisphosphonate once it has been revascularised [22]. Furthermore, blocking necrotic bone resorption, as in the case of a bone graft, may require higher local concentrations, which may be difficult to achieve with systemic treatment [23]. Such problems would be solved if the graft could be treated before implantation.

### **Local administration of bisphosphonates in combination with allografts: animal studies**

Allograft pretreated with a bisphosphonate might protect the graft from being resorbed, without affecting the entire skeleton [24]. Higher local concentrations of the drug can be used when compared to the systemic administered concentration of the drug. Bisphosphonate solution has been administered locally in combination with allograft bone in animal studies. However, all studies used different species, bisphosphonates and techniques, and showed different findings. Table 2.1 gives an overview of studies using local application of bisphosphonates and their results.

**Table 2.1** Overview of studies in which bisphosphonates are locally applied in combination with allograft bone

Study	Positive/ negative effect	Rinsing	Impaction	Bisphosphonate used/dose	Species	Method
Belfrage et al., 2011 [28]	-	-	-	Zoledronate 4 µg per graft	Rats	Combined with BMP-7 N=34 6 weeks evaluation
Jakobsen et al., 2007 [25]	-	-	+	Alendronate 2mg/mL	Dogs	N=10, each dog 4 implants 4 and 12 weeks evaluation
Tagil et al., 2004 [29]	+	+		Alendronate 1 mg/ml	Rats	N=16 6 weeks evaluation
Jeppson et al., 2003 [26]	+ /low density - /high density	+	+	Clodronate 60 mg/ml	Rats	Combined with OP-1, 2 densities N=112 6 weeks evaluation
Baas et al. , 2008 [27]	-	-	-	Pamidronate 9 mg/mL	Dogs	Combined with BMP-2 N=16, each dog 4 implants 4 weeks evaluation
Tagil et al., 2006 [22]	+	N/A	-	Zoledronate injection in donor rats 0.7 mg	Rats	Zoledronate systemically injected in donor rats, before harvesting allograft bone N=16 6 weeks evaluation



Agholme and Aspenberg, 2009 [24]	+	Depending on dose	-	2 alendronate groups and a control group 2.0 mg/mL without rinsing and 2.0 mg/mL with rinsing	Rats	N=70 4 weeks evaluation
Jakobsen et al., 2010 [31]	+	Depending on dose	+	3 zoledronate groups and a control group 0.005 mg/mL, 0.05 mg/mL, 0.5 mg/mL	Dogs	N=10, each dog 4 implants 4 weeks evaluation
Mathijssen et al., 2012 [32]	+	Depending on dose	+	Alendronate in 4 concentrations and a control group 0.5 mg/mL, 1 mg/mL, 2 mg/mL, and 10 mg/mL	Goats	1 group combined with DBM N=25, each goat 8 implants 12 weeks evaluation
Kesteris and Aspenberg, 2006 [23]	+	+	+	Ibandronate 60mg/ml	Humans	N=16 24 months evaluation

Jakobsen et al. [25] used alendronate to impregnate the allograft before impaction in a dog model. Results were compared to allograft bone which was not impregnated with a bisphosphonate. Their results showed that the formation of new bone was inhibited in the alendronate groups, when compared to the control groups. Furthermore, alendronate decreased the biomechanical implant fixation and preserved the allograft. Jeppson et al. [26] studied allograft bone in bone conduction chambers in 42 rats. The allograft bone was impacted, impregnated with clodronate and rinsed three times with saline to wash away unbound bisphosphonate. Moreover, osteogenic protein 1 (OP-1) was added to the allograft-clodronate combination to stimulate bone formation. Two different bone densities of the bone grafts were used, unimpacted bone with a bone density of 38% and impacted bone with a bone density of 64%. After six weeks, bone density had greatly increased in both groups, however the ingrowth distance of new bone in the densely impacted group was reduced. They concluded that there might be a physical obstacle that prevents cells from entering the graft, if the graft is densely impacted. Also, Baas et al. [27] were not able to change the balance between bone formation and bone resorption. The bisphosphonate pamidronate virtually blocked bone metabolism in their study. Moreover, Belfrage et al. [28] studied zoledronate without rinsing the graft before use and concluded that it might have a negative effect on bone formation and bone ingrowth. On the contrary, it has been shown that local bisphosphonate treatment can protect the graft from resorption during the early postoperative period. Tagil et al. showed this in 2 different studies [22, 29] with different bisphosphonates (zoledronate and alendronate, respectively). In both studies, bone graft in a bone conduction chamber in rats, not pre-treated with a bisphosphonate was resorbed after six weeks. In contrast, the bone chambers with graft bone which was pre-treated with a bisphosphonate were filled with dense trabecular bone consisting of both new bone and bone graft.

These contradictory results led to hypothesis that large, locally applied amounts of bisphosphonate would have a negative effect on bone formation. Therefore, Agholme et al. [24] conducted a bone chamber study in rats, in which an excessive amount of alendronate was tested. The amount tested was 2 mg/mL, however, grafts were not rinsed after impregnation. Also, an allograft group with an amount (2 mg/mL, with rinsing of the graft after impregnation) of bisphosphonate of which the positive effect on bone formation had been shown earlier [30], and a control group were studied. No differences between the two bisphosphonate groups or negative effects on the bone grafts could be found. Their results showed protection of the graft and increased bone ingrowth in the alendronate

groups. Jacobsen et al [31] studied impacted morselized allograft bone impregnated with three different doses of zoledronate in dogs: 0.005 mg/mL, 0.05mg/mL and 0.5 mg/mL. They found a dose-dependent difference in the mechanical fixation of the implants, which was defined as the shear strength, shear stiffness and the energy absorption. Best mechanical implant fixation was found in the low dose and control groups. Also, no new bone formation was observed around the implants in the group with the highest dose of zoledronate. Formation of new bone on the surface of the implants in the high-dose group was blocked. A third study on dose effects of bisphosphonates was conducted by our research group [32]. 25 goats received 8 bone conduction chambers each with impacted allograft bone which was impregnated with different alendronate solutions: 0.5 mg/mL, 1 mg/mL, 2 mg/mL, and 10 mg/mL. In accordance with the results of Jacobsen et al. [31], high doses of bisphosphonate had a negative effect on bone formation.

It is difficult to compare these three studies, since different models, species and bisphosphonates were used. Both Agholme et al. [24] as well as our research group [32] used alendronate to impregnate the allograft bone. The highest dose in the study of Agholme et al. was 2 mg/ml, without rinsing the allograft with saline after impregnation, with no negative effect on bone formation. This dose was also evaluated in a study by our group in which a decrease in bone formation was found after rinsing the allograft with saline after impregnation with alendronate in a goat model. However, highest impact on bone formation was found at a concentration of 10 mg/ml, which was much higher than the highest concentration used in the study of Agholme et al. Moreover, Agholme et al. used a rat model and did not impact the allograft bone. Jacobsen et al. [31] used zoledronate in combination with impacted allograft in a dog model, which makes it difficult to compare concentrations.

Most studies mentioned above were performed using bone chambers in different animal models. Caution should be taken when extrapolating the results to the human situation. The bone chamber model used is un-loaded and therefore quite different from the loaded conditions as in a clinical situation. Also, no cement has been applied, as is done in a cemented revision hip arthroplasty with bone impaction grafting, and other factors like vascularity, composition of the host bone bed and its interaction with the bone graft are not included in these studies.

It can be concluded that local administration of bisphosphonates combined with allograft bone is effective in protection against resorption of the allograft bone in animal models. This might increase implant fixation after procedures in which allograft bone in

combination with a prosthesis has been used. The use of bisphosphonates might therefore be suitable if structural support is needed from the graft. In cases in which no structural support is needed the inhibition of resorption of allograft bone plays a less important role. There is an optimum concentration for local use of bisphosphonates in combination with allograft bone, however, this optimum varies for all different bisphosphonates. Studies, in which impacted allograft bone was used, show that impaction did not have an adverse effect on bone remodeling. However, if the allograft bone is too densely impacted, bone remodeling might be impaired.

### **Local administration of bisphosphonates in combination with allografts: studies in humans**

To the best of our knowledge, there is only one study in humans that combined local application of bisphosphonates with allograft bone (Table 2.1). Kesteris and Aspenberg [23] soaked allograft bone in an ibandronate solution and used the bone grafts during hip revision surgeries. Patients were followed up to 24 months and were compared to controls, which were treated with placebo solution. DEXA scans were taken to study bone density. They concluded that rinsing of morselized bone grafts with bisphosphonates prevents resorption and is likely to reduce the risk of mechanical failure. In control patients the grafts were already partially resorbed after three months, whereas the grafts treated with bisphosphonate increased in density postoperatively and then remained unchanged for two years. However, long-term follow-up is not available and the application of bisphosphonates in combination with allografts in humans has to be studied in more detail.

### **Effects on osteoblasts**

Although the primary action of bisphosphonates is to inhibit the osteoclasts, there is increasing evidence that bisphosphonates also interact with osteoblasts. Bisphosphonates might enhance proliferation and maturation of osteoblasts, and inhibit apoptosis, leading to increased bone formation [33]. These anabolic effects of bisphosphonates on bone formation are confirmed in several *in vitro* [34-38] and *in vivo* studies [7]. In animal studies on local administration of bisphosphonates combined with allograft bone, the amount of new bone increased significantly when compared to the control group, if the graft was pretreated with a bisphosphonate [30-32, 39, 40]. A possible explanation of the increase in newly formed bone, might be the rapid remodeling by osteoclasts. In grafts

not treated with a bisphosphonate, osteoblasts form new bone, however, osteoclasts immediately resorb the newly formed bone. In grafts treated with a bisphosphonate the newly formed bone is not resorbed. This yields a net higher amount of new bone, which is entirely the result of the inhibition of osteoclastic activity and might explain the differences observed. Another explanation for the increase in newly formed bone has been proposed by Jakobsen et al. [31] They stated that the increase in bone formation might be explained by the preserving effect of the bisphosphonate on the allograft, thereby prolonging the osteoconductive effect. A third explanation for the decrease in newly formed bone in the presence of high doses of bisphosphonates might be the lack of space. The necrotic, allograft bone is not resorbed and therefore, no room is left for the formation of new bone.

At a high dose, bisphosphonates have been shown to be toxic to osteoblasts [37, 41]. Iwata et al. [42] concluded that bisphosphonates suppress osteoblastic activity at bone remodeling sites. It has been suggested that at a high dose bisphosphonates might have a cytotoxic effect on the osteoblasts [13, 38]. Naidu et al. [38] concluded that the effect of zoledronate on proliferation was dependent on its concentration, with a clear cut-off concentration. These cut-off and cytotoxic concentrations vary for each type of bisphosphonate.

## Conclusion

Systemic administrated bisphosphonates might protect allograft bone from too fast resorption, however, only vascularized bone can be reached. The allograft bone can only be reached by the bisphosphonate once it has been revascularized. However, this can be circumvented by local administration of bisphosphonates. Local administration protects the graft from resorption and might stimulate bone formation. There is an optimum concentration for local use, however, this optimum varies for all different bisphosphonates. If the local concentration of the bisphosphonate is too high, bone metabolism is blocked, which has a negative influence on bone ingrowth and mechanical stability.

Local administration of bisphosphonates might play an important role in improving implant stability after surgery in which allograft bone is used to restore bony defects, however, however caution should be taken when extrapolation results of animal research to the human clinical situation. More research has to be done to study the effect of local use of bisphosphonates in humans.

## REFERENCES

1. Russell RG: **Bisphosphonates: the first 40 years.** *Bone* 2011, **49**(1):2-19.
2. Aspenberg P: **Bisphosphonates and implants: an overview.** *Acta Orthop* 2009, **80**(1):119-123.
3. Aberg J, Brohede U, Mihranyan A, Stromme M, Engqvist H: **Bisphosphonate incorporation in surgical implant coatings by fast loading and co-precipitation at low drug concentrations.** *J Mater Sci Mater Med* 2009, **20**(10):2053-2061.
4. Barou O, Mekraldi S, Vico L, Boivin G, Alexandre C, Lafage-Proust MH: **Relationships between trabecular bone remodeling and bone vascularization: a quantitative study.** *Bone* 2002, **30**(4):604-612.
5. Russell RG, Rogers MJ, Frith JC, Luckman SP, Coxon FP, Benford HL, Croucher PI, Shipman C, Fleisch HA: **The pharmacology of bisphosphonates and new insights into their mechanisms of action.** *J Bone Miner Res* 1999, **14** Suppl 2:53-65.
6. Fleisch H: **Bisphosphonates: mechanisms of action.** *Endocr Rev* 1998, **19**(1):80-100.
7. von Knoch F, Eckhardt C, Alabre CI, Schneider E, Rubash HE, Shanbhag AS: **Anabolic effects of bisphosphonates on peri-implant bone stock.** *Biomaterials* 2007, **28**(24):3549-3559.
8. Hilding M, Aspenberg P: **Postoperative clodronate decreases prosthetic migration: 4-year follow-up of a randomized radiostereometric study of 50 total knee patients.** *Acta Orthop* 2006, **77**(6):912-916.
9. Hilding M, Aspenberg P: **Local peroperative treatment with a bisphosphonate improves the fixation of total knee prostheses: a randomized, double-blind radiostereometric study of 50 patients.** *Acta Orthop* 2007, **78**(6):795-799.
10. Slooff TJ, Huiskes R, van Horn J, Lemmens AJ: **Bone grafting in total hip replacement for acetabular protrusion.** *Acta Orthop Scand* 1984, **55**(6):593-596.
11. Gie GA, Linder L, Ling RS, Simon JP, Slooff TJ, Timperley AJ: **Impacted cancellous allografts and cement for revision total hip arthroplasty.** *J Bone Joint Surg Br* 1993, **75**(1):14-21.
12. Hilding M, Ryd L, Toksvig-Larsen S, Aspenberg P: **Clodronate prevents prosthetic migration: a randomized radiostereometric study of 50 total knee patients.** *Acta Orthop Scand* 2000, **71**(6):553-557.
13. Peter B, Ramaniraka N, Rakotomanana LR, Zambelli PY, Pioletti DP: **Peri-implant bone remodeling after total hip replacement combined with systemic alendronate treatment: a finite element analysis.** *Comput Methods Biomech Biomed Engin* 2004, **7**(2):73-78.
14. Arabmotlagh M, Pilz M, Warzecha J, Rauschmann M: **Changes of femoral periprosthetic bone mineral density 6 years after treatment with alendronate following total hip arthroplasty.** *J Orthop Res* 2009, **27**(2):183-188.
15. Arabmotlagh M, Rittmeister M, Hennigs T: **Alendronate prevents femoral periprosthetic bone loss following total hip arthroplasty: prospective randomized double-blind study.** *J Orthop Res* 2006, **24**(7):1336-1341.

16. Wilkinson JM, Stockley I, Peel NF, Hamer AJ, Elson RA, Barrington NA, Eastell R: **Effect of pamidronate in preventing local bone loss after total hip arthroplasty: a randomized, double-blind, controlled trial.** *J Bone Miner Res* 2001, **16**(3):556-564.
17. Yamasaki S, Masuhara K, Yamaguchi K, Nakai T, Fuji T, Seino Y: **Risedronate reduces postoperative bone resorption after cementless total hip arthroplasty.** *Osteoporos Int* 2007, **18**(7):1009-1015.
18. Venesmaa PK, Kroger HP, Miettinen HJ, Jurvelin JS, Suomalainen OT, Alhav EM: **Alendronate reduces periprosthetic bone loss after uncemented primary total hip arthroplasty: a prospective randomized study.** *J Bone Miner Res* 2001, **16**(11):2126-2131.
19. Astrand J, Harding AK, Aspenberg P, Tagil M: **Systemic zoledronate treatment both prevents resorption of allograft bone and increases the retention of new formed bone during revascularization and remodelling. A bone chamber study in rats.** *BMC Musculoskelet Disord* 2006, **7**:63.
20. Benhamou CL: **Effects of osteoporosis medications on bone quality.** *Joint Bone Spine* 2007, **74**(1):39-47.
21. Khan AA, Sandor GK, Dore E, Morrison AD, Alsahli M, Amin F, Peters E, Hanley DA, Chaudry SR, Lentle B *et al*: **Bisphosphonate associated osteonecrosis of the jaw.** *J Rheumatol* 2009, **36**(3):478-490.
22. Tagil M, Aspenberg P, Astrand J: **Systemic zoledronate precoating of a bone graft reduces bone resorption during remodeling.** *Acta Orthop* 2006, **77**(1):23-26.
23. Kesteris U, Aspenberg P: **Rinsing morcellised bone grafts with bisphosphonate solution prevents their resorption. A prospective randomised double-blinded study.** *J Bone Joint Surg Br* 2006, **88**(8):993-996.
24. Agholme F, Aspenberg P: **Experimental results of combining bisphosphonates with allograft in a rat model.** *J Bone Joint Surg Br* 2009, **91**(5):670-675.
25. Jakobsen T, Baas J, Bechtold JE, Elmengaard B, Soballe K: **Soaking morselized allograft in bisphosphonate can impair implant fixation.** *Clin Orthop Relat Res* 2007, **463**:195-201.
26. Jeppsson C, Astrand J, Tagil M, Aspenberg P: **A combination of bisphosphonate and BMP additives in impacted bone allografts.** *Acta Orthop Scand* 2003, **74**(4):483-489.
27. Baas J, Elmengaard B, Jensen TB, Jakobsen T, Andersen NT, Soballe K: **The effect of pretreating morselized allograft bone with rhBMP-2 and/or pamidronate on the fixation of porous Ti and HA-coated implants.** *Biomaterials* 2008, **29**(19):2915-2922.
28. Belfrage O, Flivik G, Sundberg M, Kesteris U, Tagil M: **Local treatment of cancellous bone grafts with BMP-7 and zoledronate increases both the bone formation rate and bone density: a bone chamber study in rats.** *Acta Orthop* 2011, **82**(2):228-233.
29. Tagil M, Astrand J, Westman L, Aspenberg P: **Alendronate prevents collapse in mechanically loaded osteochondral grafts: a bone chamber study in rats.** *Acta Orthop Scand* 2004, **75**(6):756-761.
30. Aspenberg P, Astrand J: **Bone allografts pretreated with a bisphosphonate are not resorbed.** *Acta Orthop Scand* 2002, **73**(1):20-23.

31. Jakobsen T, Baas J, Bechtold JE, Elmengaard B, Soballe K: **The effect of soaking allograft in bisphosphonate: a pilot dose-response study.** *Clin Orthop Relat Res* 2010, **468**(3):867-874.
32. Mathijssen NM, Hannink G, Pilot P, Schreurs BW, Bloem RM, Buma P: **Impregnation of bone chips with alendronate and cefazolin, combined with demineralized bone matrix: a bone chamber study in goats.** *BMC Musculoskelet Disord* 2012, 13:44.
33. von Knoch F, Jaquiere C, Kowalsky M, Schaeren S, Alabre C, Martin I, Rubash HE, Shanbhag AS: **Effects of bisphosphonates on proliferation and osteoblast differentiation of human bone marrow stromal cells.** *Biomaterials* 2005, **26**(34):6941-6949.
34. Ozturk AM, Tabak AY, Aktekin CN, Altay M, Erdemli E, Karahuseyinoglu S, Korkusuz F: **Alendronate enhances antibiotic-impregnated bone grafts in the treatment of osteomyelitis.** *Int Orthop* 2008, **32**(6):821-827.
35. Im GI, Qureshi SA, Kenney J, Rubash HE, Shanbhag AS: **Osteoblast proliferation and maturation by bisphosphonates.** *Biomaterials* 2004, **25**(18):4105-4115.
36. Reinholz GG, Getz B, Pederson L, Sanders ES, Subramaniam M, Ingle JN, Spelsberg TC: **Bisphosphonates directly regulate cell proliferation, differentiation, and gene expression in human osteoblasts.** *Cancer Res* 2000, **60**(21):6001-6007.
37. Gangoiti MV, Cortizo AM, Arnol V, Felice JI, McCarthy AD: **Opposing effects of bisphosphonates and advanced glycation end-products on osteoblastic cells.** *Eur J Pharmacol* 2008, **600**(1-3):140-147.
38. Naidu A, Dechow PC, Spears R, Wright JM, Kessler HP, Opperman LA: **The effects of bisphosphonates on osteoblasts in vitro.** *Oral Surg Oral Med Oral Pathol Oral Radiol Endod* 2008, **106**(1):5-13.
39. Astrand J, Aspenberg P: **Systemic alendronate prevents resorption of necrotic bone during revascularization. A bone chamber study in rats.** *BMC Musculoskelet Disord* 2002, 3:19.
40. Jakobsen T, Kold S, Bechtold JE, Elmengaard B, Soballe K: **Local alendronate increases fixation of implants inserted with bone compaction: 12-week canine study.** *J Orthop Res* 2007, **25**(4):432-441.
41. Orriss IR, Key ML, Colston KW, Arnett TR: **Inhibition of osteoblast function in vitro by aminobisphosphonates.** *J Cell Biochem* 2009, **106**(1):109-118.
42. Iwata K, Li J, Follet H, Phipps RJ, Burr DB: **Bisphosphonates suppress periosteal osteoblast activity independently of resorption in rat femur and tibia.** *Bone* 2006, **39**(5):1053-1058.



## CHAPTER 3

# IMPREGNATION OF BONE CHIPS WITH ALENDRONATE, CEFAZOLIN AND DEMINERALIZED BONE MATRIX: A BONE CHAMBER STUDY IN GOATS

Nina M.C. Mathijssen, Gerjon Hannink, Peter Pilot, B. Wim Schreurs, Rolf M. Bloem, Pieter Buma.

(BMC Musculoskelet Disord. 2012 Mar 24;13:44)

Doi:10.1186/1471-2474-13-44

## ABSTRACT

**Background:** Bone grafts from bone banks might be mixed with bisphosphonates to inhibit the osteoclastic response. This inhibition prevents the osteoclasts to resorb the allograft bone before new bone has been formed by the osteoblasts, which might prevent instability. Since bisphosphonates may not only inhibit osteoclasts, but also osteoblasts and thus bone formation, we studied different bisphosphonate concentrations combined with allograft bone. We investigated whether locally applied alendronate has an optimum dose with respect to bone resorption and formation. Further, we questioned whether the addition of demineralized bone matrix (DBM), would stimulate bone formation. Finally, we studied the effect of high levels of antibiotics on bone allograft healing, since mixing allograft bone with antibiotics might reduce the infection risk.

**Methods:** 25 goats received eight bone conduction chambers in the cortical bone of the proximal medial tibia. Five concentrations of alendronate (0, 0.5 mg/mL, 1 mg/mL, 2 mg/mL, and 10 mg/mL) were tested in combination with allograft bone and supplemented with cefazolin (200 µg/mL). Allograft not supplemented with alendronate and cefazolin served as control. In addition, allograft mixed with demineralized bone matrix, with and without alendronate, was tested. After 12 weeks, graft bone area and new bone area were determined with manual point counting.

**Results:** Graft resorption decreased significantly ( $p < 0.001$ ) with increasing alendronate concentration. The area of new bone in the 1 mg/mL alendronate group was significantly ( $p = 0.002$ ) higher when compared to the 10 mg/mL group. No differences could be observed between the group without alendronate, but with demineralized bone, and the control groups.

**Conclusions:** A dose-response relationship for local application of alendronate has been shown in this study. Most new bone was present at 1 mg/mL alendronate. Local application of cefazolin had no effect on bone remodelling.

## BACKGROUND

Different types of bone grafts from bone banks are widely used for the restoration of bone defects in clinical practice with satisfying clinical outcomes [1, 2]. In addition, allograft bone bank chips are used during bone impaction grafting, a well-accepted and clinical successful procedure for the restoration of bone stock loss around loose implants [3-5]. This procedure is hence applied during revision arthroplasty. A possible problem associated with the use of bone grafts in loaded conditions, like in revisions, is a too fast resorption of graft material. Accelerated bone graft resorption before the formation of new bone may cause loss of stability, ultimately resulting in failure of the revised hip or knee implant [6-8].

Bisphosphonates might reduce bone graft resorption by inhibition of the osteoclasts [9]. Bisphosphonates have a high affinity for  $\text{Ca}^{2+}$ , and therefore are targeted to areas of high bone turnover and adhere closely and selectively to sites of active bone remodelling. Osteoclasts trying to resorb the bone, release the bisphosphonates from the bone mineral. Bisphosphonates become internalized in the osteoclast, resulting in apoptosis of the osteoclast [10].

Although bisphosphonates efficiently suppress bone resorption by apoptosis of osteoclasts, systemic treatment will only reach the revascularized parts of the bone graft and the concentration of bisphosphonates in regions of the skeleton with low blood perfusion, for example the femoral neck, will be very low [11-13]. Therefore, in several studies a bisphosphonate solution was administered locally, with varying results [9, 12, 14-17]. In these studies, it was hypothesized that local application of bisphosphonates would decrease resorption after implantation of a new prosthesis. This might prevent mechanical instability and therefore provide better support during the early process of healing after the operation. This way, bone resorption and bone formation might be more balanced. Baas et al. [16] were not able to change this balance between bone formation and bone resorption. The bisphosphonate virtually blocked bone metabolism in their study. In addition, Jakobsen et al. [15] found a substantially decreased biomechanical implant fixation when the impacted morselized allograft had been soaked in bisphosphonate. On the contrary, it has been shown that local bisphosphonate treatment can protect the graft from resorption during the early postoperative period [9, 12]. It has been suggested that bisphosphonates not only inhibit osteoclastic activity, but also might have a decreased anabolic or even a toxic effect on osteoblasts; a too high concentration of the unbound bisphosphonate may not only inhibit the osteoclasts but also the osteoblasts, and thus

reduce new bone formation [18]. It is therefore important that the concentration of unbound free bisphosphonate is below the level in which osteoblasts are inhibited [9, 15, 16, 19, 20].

The chance of failure of a reconstruction is greatest immediately after surgery, when the graft bone has not been incorporated yet. This critical period after reconstruction with bone impaction grafting might be shortened when demineralized bone matrix (DBM) is used. DBM is a product of processed allograft bone and contains collagen, proteins and growth factors [21]. Demineralization of bone theoretically facilitates the release of growth factors which could increase the bioactivity of the graft and positively influence new bone formation and thus the amount of new bone [22, 23] which might be of importance during the early critical period.

Another devastating complication following joint replacement surgery is infection. Systemic administered antibiotics are widely used to prevent and cure infection, however these antibiotics cannot easily reach the infected bone in an avascular area [24]. In addition, formation of a biofilm on the surface of the implant makes the systemic administered antibiotics less effective [25]. A solution to achieve high local antibiotic concentrations is to impregnate bone allograft chips with antibiotics. Several studies have shown that morselized bone can act as a carrier for antibiotics [26-32]. These studies show, both *in vitro* as *in vivo*, that bone grafts impregnated with antibiotics can be used as a prophylaxis against infections. However, the effectiveness of bone allograft healing in the presence of high levels of antibiotics has yet to be determined.

In this study we combined the local application of bisphosphonate, DBM and antibiotics with allograft bone chips in a bone chamber. The purpose of this study was to investigate the dose-response relation of alendronate-impregnated allograft with respect to the amount of graft bone and the amount of new bone or total bone after 12 weeks. We investigated whether locally applied alendronate has an optimum dose with respect to bone resorption and net bone formation. The second question of this study was whether the addition of DBM to bone chips impregnated with bisphosphonate would stimulate bone formation. Finally, we investigated whether the local application of antibiotics has an effect on bone remodelling.

## METHODS

### Study design

25 mature Dutch female goats (*Capra Hircus Sana*, range 49-70 kg) bilaterally received four bone chambers in the cortical bone of the proximal medial tibia. The side and position of implantation of the 8 chambers were alternated with a random start. The bone conduction chamber consists of a titanium screw with a cylindrical interior space [33]. It is made up of two threaded half-cylinders held together by a hexagonal closed screw cap. The interior of the chamber has a diameter of 2 mm and a length of 7.5 mm. There are two openings at the end of the chamber to enable bone ingrowth. The threaded end of the implant is screwed into the tibia of the goat, so that the ingrowth openings are in direct contact with the endosteal transition from marrow into bone. Originally developed as a rat model, the bone conduction chamber was adjusted for use in goats [34]. Since the tibial cortex in rats is thinner than in goats, a 1-mm thick plate was inserted into the cap to lower the ingrowth openings through the cortex.

Five concentrations of bisphosphonates (0, 0.5, 1, 2, and 10 mg/mL alendronate, Fosamax, MSD) were combined with allograft bone supplemented with antibiotics (200 µg/mL cefazolin) (ALL+AB, ALL+AB+0.5BIS, ALL+AB+1BIS, ALL+AB+2BIS, and ALL+AB+10BIS). Allograft not supplemented with alendronate and cefazolin served as control (ALL). In addition, allograft mixed with DBM with alendronate (1 mg/mL) (ALL+DBM+BIS) and without alendronate (ALL+DBM) were tested (Table 3.1). The observation time was 12 weeks.

**Table 3.1** Overview of experimental design

Group	Alendronate (mg/mL)	Cefazolin (µg/mL)	DBM
ALL	-	-	-
ALL+AB	-	200	-
ALL+AB+0.5BIS	0.5	200	-
ALL+AB+BIS	1	200	-
ALL+AB+2BIS	2	200	-
ALL+AB+10BIS	10	200	-
ALL+DBM	-	-	+
ALL+DBM+BIS	1	-	+

Our sample size calculation was based on the results of a study of Aspenberg and Astrand [9]. The minimal relevant difference of bone formation was set to 27% and based on this study, we assumed the standard deviation on the relative change to be 8%. Two sided  $\alpha$  and  $\beta$  were set to be 5% and 10% respectively.

All procedures were approved by our institutional Animal Ethics Committee.

### **Bone graft preparation**

Cancellous bone graft was obtained under sterile conditions from the sternum of three donor goats. Bone grafts were morselized into chips of approximately 1–2 mm, pooled and rinsed with saline with pulse lavage (Pulsavac® Plus, Zimmer, Swindon, UK) for two minutes to remove blood and marrow.

Bone chips were impregnated with 5 ml alendronate (Fosamax, MSD) and/or 5 ml cefazolin solutions for 10 minutes, then rinsed 3 times in 5 ml saline at room temperature for 3 minutes. Rinsing was done to remove unbound and excessive alendronate and/or cefazolin. Alendronate solution was prepared by dissolving one 10 mg tablet in 5 ml of saline for 1 hour and then passing it through a sterile Millipore filter with a pore size of 0.2 mm. To obtain the different concentrations, this alendronate solution was diluted.

The concentration of cefazolin was 200  $\mu\text{g}/\text{mL}$ . This concentration was based on an earlier performed *in vitro* study, in which the amount of antibiotics on the allograft bone was determined after impregnation of the bone chips with cefazolin [35]. The amount of cefazolin present on the bone chips after rinsing 3 times with saline was determined and appeared to be well above the Minimal Inhibitory Concentration (MIC) for *S. Epidermidis* and about 1/3 of the amount of cefazolin present on the bone chips without rinsing. Additional data (unpublished) showed that impacting the bone graft chips after impregnation with cefazolin, did not have an effect on the amount of cefazolin present on the bone chips, compared to not impacting the bone chips. Tests were performed according to the protocol as described earlier [35]. According to Edin et al. [36], local levels of cefazolin of 200  $\mu\text{g}/\text{mL}$  decrease cell replication, but local levels of 100  $\mu\text{g}/\text{mL}$  do not affect the replication of osteoblasts. Freeze-dried DBM (size 80–800  $\mu\text{m}$ ) was prepared at DIZG (Deutsches Institut für Zell- und Gewebeersatz, Berlin, Germany) from the cortical bone of two donor goat femora under sterile conditions. DBM was rehydrated and mixed with the cancellous bone graft chips in a 50/50 volume ratio.

Impaction was performed by gradually filling the chambers with the allograft preparations. A piston slightly smaller in diameter (1.9 mm) was used for impaction. The piston was guided by low friction bearings, strictly limiting it to vertical movement. During impaction, the chamber was clamped into a cylindrical holder. A constant force of 40N was kept on the free end of the piston for two minutes. During this time, fluid could escape between the piston and the wall of the bone chamber and the ingrowth openings. The pressure applied was calculated to be 25 MPa. With this method of impaction, the mean volume fraction of graft bone in the bone chamber rises from about 35% in unimpacted grafts to about 65% in impacted ones [37]. After impaction, the screw cap was placed on the cylinder and the bone conduction chamber was stored at  $-80^{\circ}\text{C}$  until use. The bone chambers were thawed at room temperature before implantation.

### **Surgical procedure**

Goats were anesthetized with medetomidine (5  $\mu\text{g}/\text{kg}$ ) and propofol (3–5  $\text{mg}/\text{kg}$ ), intubated, and maintained using isoflurane and oxygen in a semiclosed ventilation system. The goats were placed in supine position. The lower legs were shaved, washed, iodized and covered with sterile cloths. A longitudinal incision was made in the skin and fascia over the medial side of the proximal tibia. The cortical bone was explored and a hole was drilled through the medial cortex at approximately 4 cm from the joint cleft using a 3.2-mm drill. The hole was tapped and bone debris from drilling was removed. The bone conduction chamber was screwed in manually. The other three bone conduction chambers were placed 10 mm from each other. This was repeated for the other side. The skin was sutured in two layers.

After the operation, goats received injections of antibiotics (15  $\text{mg}/\text{kg}$ ) (ampicilline) and analgetics (1  $\text{mg}/\text{kg}$ ) (flunixin). All animals were allowed unrestricted movement in their cages and had free access to water and food after the operation. After 12 weeks, the goats were killed with an overdose of sodium pentobarbital (0.5  $\text{mL}/\text{kg}$ ).

### **Histological and histomorphometric evaluation**

Tibiae were removed and the bone conduction chambers with surrounding cortex were fixed in 4% buffered formalin. After 1 day the contents were removed from the bone chambers and fixed additionally for at least 5 days. After dehydration in ethanol and plastic embedding (polymethylmethacrylate), non-decalcified 7-mm thick serial sections were

made along the longitudinal axis of the specimen. Sections were stained with hematoxylin and eosin and Goldner-Masson for routine histological analysis. Histomorphometric quantitative analysis was done blindly using digitalized pictures of the sections. Three central sections in each specimen were studied, each 250  $\mu\text{m}$  apart. Manual point counting was performed using custom-made stereological software. The total number of points, points covering bone in general and points covering new living bone were counted. Graft bone was identified by its highly organized lamellas and oval cell lacunae without nucleic material, whereas newly formed bone was less organized and contained nucleic material. On average, 100 point were counted in each section, resulting in 300 points per specimen. All sections were blinded and evaluated in random order.

## Statistics

Results were analysed non-parametrically, therefore Friedman's repeated measurements ANOVA on ranks with a Wilcoxon signed ranks test with a Bonferroni adjustment was used to differentiate between groups.

SPSS software version 18.0 was used. Statistical significance was set at  $p < 0.05$ .

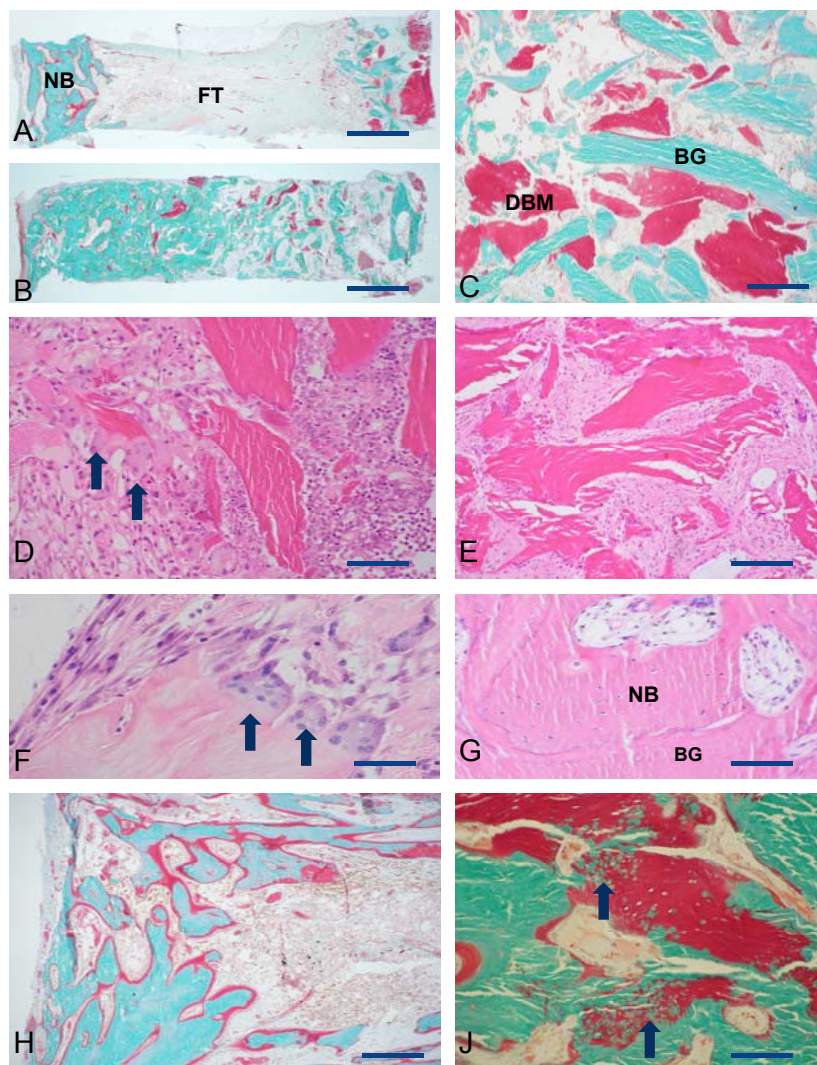
## RESULTS

All goats were able to stand normally on their hind legs 1 to 2 days after surgery. There were no signs of inflammation, skin ulceration or wound healing problems. Three goats died during the 12 week period, of reasons not related to surgery. These goats were not excluded from analysis, since they died a few days before sacrifice. 8 bone chambers were loose and excluded, they originated from the control group (1), control with cefazolin group (2), 0.5 mg/mL alendronate group (1), 2 mg/mL alendronate group (1), 10mg/mL alendronate group (2) and of the DBM group (1).

## Histology

In general, bone chambers were surrounded by a layer of callus and covered with fibrous tissue. The graft bone in the control group was almost entirely resorbed (Figure 3.1A), while in the alendronate groups the bone chambers were full with graft bone as well as new bone (Figure 3.1B). A homogeneous distribution of DBM was present in non-resorbed areas within the bone chamber (Figure 3.1C). Two different incorporation patterns were





**Figure 3.1** Histological results. **A.** Typical example of ALL+DBM group. Notice large area of fibrous tissue (FT) between graft remnants (right) and new bone (NB). **B.** Typical example of BIS+DBM group. Bone chamber is fully filled with a mixture of graft remnants, DBM and new bone. **C.** Non incorporated mixture of bone graft (BG) and demineralized bone (DBM) of ALL+DBM+BIS group. **D.** The incorporation front in a chamber with ALL. Arrows point at osteoclasts. **E.** Fibrous tissue surrounding bone grafts. ALL+AB+2BIS group. **F.** Osteoclasts on DBM bone particle. ALL+DBM group. **G.** Enlargement of bone in ALL+AB+2BIS group. Notice mixture of new bone (NB) with osteocytes and bone graft (BG). **H.** New bone formed in ALL+DBM group. **J.** Ossification (arrows) of BIS particles in bone chamber of ALL+DBM+BIS group. Bars are 1 mm (A, B), 500  $\mu$  (H), 250  $\mu$  (C, D, E, J) or 100  $\mu$ m (F, G).

found in the ALL, ALL+AB, ALL+DBM groups on the one hand (Figure 3.1A) and all the other groups where BIS was added on the other hand. (Figure 3.1B).

In all groups without BIS (ALL, ALL+AB, ALL+DBM) similar patterns of resorption and new bone formation were present. All bone graft (including DBM if present) was resorbed or a resorption front could be found at the interface with allograft remnants (Figure 3.1D). This front, if still present, consisted of numerous lymphocytic cells that had penetrated into the graft (Figure 3.1D). Numerous osteoclasts in a blood vessel rich area resorbed all allograft and DBM if present (Figure 3.1D). No obvious differences were found between the activity of osteoclasts on allograft bone or DBM (Figure 3.1D, 3.1F). Between the resorption front and the area with new bone in almost all chambers a thick fibrous interface was present containing fibroblasts and some macrophages (Figure 3.1A). New bone formation was mainly found at the direct vicinity of the ingrowth holes (Figure 3.1A, 3.1H). The newly formed bone contained no or scarce remnants of ALL or DBM. In most chambers a strong remodeling activity was still present as is visualized by the red non-calcified zones in the Goldner stained sections (Figure 3.1J).

In all groups with BIS the delineation of the resorption front was less clear. Lower numbers of osteoclasts were present on the bone graft particles (Figure 3.1E) compared to all groups without BIS. Histologically no clear differences could be found in the number of osteoclasts in the different BIS concentration groups. After the passage of the revascularization front through the bone graft, the non-resorbed ALL and/or DBM were surrounded by fibrous tissue (Figure 3.1E). Newly formed bone was present in a much larger area compared to all groups without BIS (Figure 3.1B). Bone was formed on the remnants of ALL or DBM (Figure 3.1G, 3.1J). No clear differences were found between the resorption of ALL and DBM. In the area with new bone most allograft bone was mineralized. In the Goldner stained sections some focal areas with non-mineralized DBM were present, but round green spots in the DBM particles suggest that they underwent a process of mineralization after incorporation into new bone (Figure 3.1J).

## **Histomorphometry**

### ***Cefazolin***

No significant differences could be observed between the cefazolin group (ALL+AB) and the control group (ALL), for total bone volume, graft bone volume or new bone volume (Table 3.2, Figure 3.2 and Figure 3.3).

**Table 3.2A** Overview of statistical results (graft bone)

Group	ALL	ALL+AB	ALL+AB +0.5BIS	ALL+AB +BIS	ALL+AB +2BIS	ALL+AB +10BIS	ALL +DBM	ALL+DBM +BIS
ALL	-	-	-	-	-	-	-	-
ALL+AB	0.674	-	-	-	-	-	-	-
ALL+AB+0.5BIS	<0.001*	<0.001*	-	-	-	-	-	-
ALL+AB+BIS	<0.001*	<0.001*	<0.001*	-	-	-	-	-
ALL+AB+2BIS	<0.001*	<0.001*	<0.001*	0.001*	-	-	-	-
ALL+AB+10BIS	<0.001*	<0.001*	<0.001*	<0.001*	0.003	-	-	-
ALL+DBM	0.003	0.003	<0.001*	<0.001*	<0.001*	<0.001*	-	-
ALL+DBM+BIS	0.008	<0.001*	0.000*	0.001*	0.003	0.361	<0.001*	-

\* Significant:  $p < 0.0018$  (Bonferroni adjustment due to 28 different comparisons).

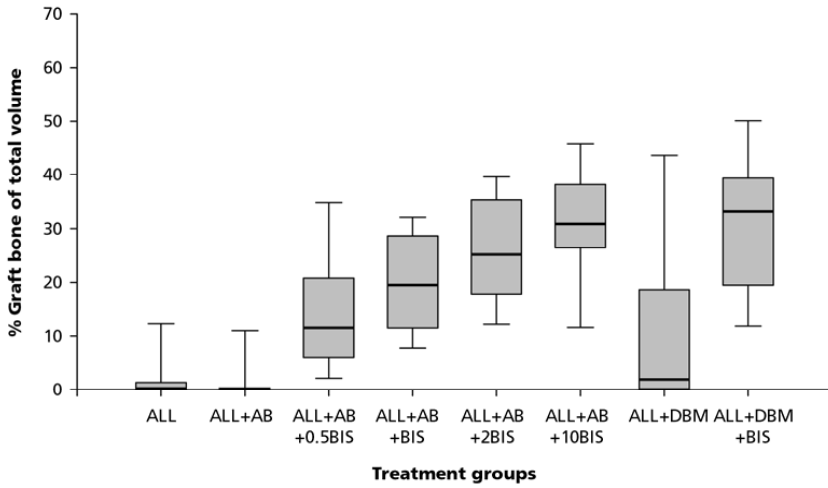
**Table 3.2B** Overview of statistical results (new bone)

Group	ALL	ALL+AB	ALL+AB +0.5BIS	ALL+AB +BIS	ALL+AB +2BIS	ALL+AB +10BIS	ALL +DBM	ALL+DBM +BIS
ALL	-	-	-	-	-	-	-	-
ALL+AB	0.068	-	-	-	-	-	-	-
ALL+AB+0.5BIS	<0.001*	0.059	-	-	-	-	-	-
ALL+AB+BIS	<0.001*	<0.001*	<0.001*	-	-	-	-	-
ALL+AB+2BIS	<0.001*	<0.001*	0.007	0.219	-	-	-	-
ALL+AB+10BIS	<0.001*	0.285	0.049	0.002	0.018	-	-	-
ALL+DBM	0.344	0.181	0.001*	<0.001*	<0.001*	<0.001*	-	-
ALL+DBM+BIS	<0.001*	0.11	0.375	<0.001*	0.043	0.331	<0.001*	-

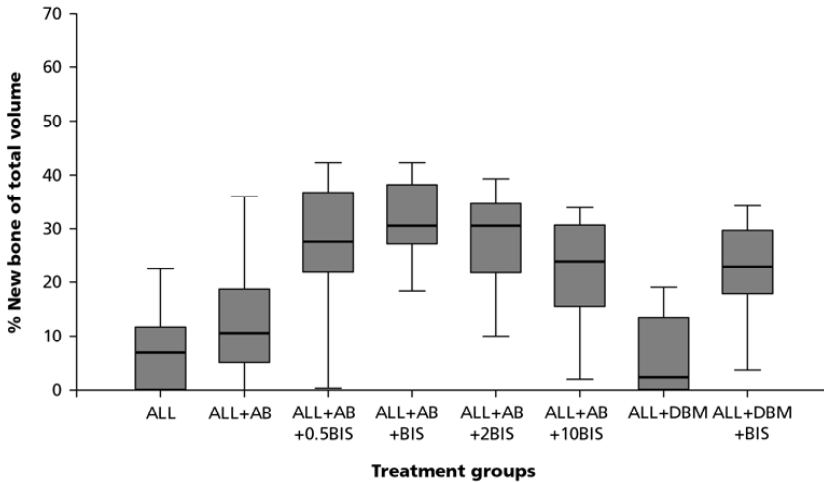
\* Significant:  $p < 0.0018$  (Bonferroni adjustment due to 28 different comparisons).

### **Alendronate**

An alendronate dose-dependent difference in the amount of graft bone was found (Table 3.2A, Figure 3.2). Graft resorption decreased with increasing alendronate concentration. All groups treated with alendronate differed significantly ( $p < 0.001$ ) when compared to the volume fraction of allograft bone of the control group. These significant differences for volume fraction of allograft bone were also observed between the four alendronate-groups; with increasing amounts of alendronate, a decrease in graft resorption was found, which were all significantly different.



**Figure 3.2** Percentage graft bone of total volume for the 8 different groups.



**Figure 3.3** Percentage new bone of total volume for the 8 different groups.

Bone formation in the four alendronate groups was significantly different when compared to the control group ( $p < 0.001$ ) (Table 3.2B, Figure 3.3).

When bone formation in the 1 mg/ml (ALL+AB+BIS) was compared to bone formation in the 10 mg/ml (ALL+AB+10BIS) group, the volume fraction of new bone was significantly lower in the highest alendronate group (Table 3.2).

### ***Demineralized bone matrix***

When the group with DMB (ALL+DBM) was compared to the control group, no differences could be observed (Table 3.2AB).

## **DISCUSSION**

The purpose of this study was to investigate the dose-response relationship of alendronate-impregnated allograft with respect to the amount of graft bone and the amount of new bone or total bone after 12 weeks in a goat bone chamber model. Also, the effects of adding DBM and the local application of antibiotics (cefazolin) were tested.

We showed a dose-response relation for local application of alendronate with respect to the amount of new bone as well as the amount of graft bone present in the bone chamber after 12 weeks. Decreased implant fixation has been observed with higher doses of bisphosphonates (by blocking bone metabolism completely) [16]. Therefore, an optimum dose regarding bone resorption is essential, since it yields a positive balance between allograft resorption and the net amount of newly formed bone which results in improved fixation.

Our results show that with increasing alendronate concentration, graft resorption decreased and the amount of necrotic graft bone, left after 12 weeks, increases. This is in accordance with the study of Jakobsen et al. [20], in which another bisphosphonate, zoledronate, was used. They also studied different bisphosphonate concentrations, however their volume fractions of allograft bone were much higher compared to our study. Our volume fractions of allograft bone were 10.9% ( $\pm$  8.8) for the lowest alendronate group to 32.8% ( $\pm$  8.7) for the highest alendronate group, while in the study of Jakobsen, graft bone volume fractions started with mean values above 30%. These differences in results might also be explained by the rinsing method used (3 min vs 10 min) or the fact that Jakobsen had a mechanically loaded situation compared to our unloaded situation. Agholme et al. [17] also used alendronate locally (2 mg/mL) and found volume fractions of allograft bone compared to ours. In contrast to our study, they did not find any differences between the amount of new bone between a regular dose (with rinsing after impregnation) of bisphosphonate and an overdose amount (without rinsing the graft after impregnation). The volume fractions of new bone were comparable to the mean volume fractions of the 4 different doses in our study, although we did find differences between the doses. They stated that their results may be explained by the four-week study period

in their experiments compared to the 6 weeks period in other studies (and thus the 12 week period in our study), that there was not enough time to fully resorb all allograft bone behind the bone ingrowth frontier.

Zoledronate is used in several studies for local application of bisphosphonate and is a more potent bisphosphonate compared to alendronate [38]. Differences in graft volume fractions between local application of alendronate and zoledronate might be explained by this. Alendronate was chosen in this study as bisphosphonate since it has been used as osteoporosis prophylaxis treatment for almost two decades [39].

The amount of new bone in our experiment showed an optimum at a dose of 1 mg/mL alendronate. The amount of new bone was significantly higher compared to control and also when compared to lower and higher alendronate concentrations.

A possible explanation for the difference in newly formed bone between control and BIS groups is that in the control groups the newly formed bone is rapidly remodeled by osteoclasts. This yields a net low amount of new bone, which is entirely the result of osteoclastic activity and might explain the differences observed. Jakobsen et al. stated that this effect could be explained by the preserving effect of the bisphosphonate on the allograft, thereby prolonging the osteoconductive effect [20].

An enhancing effect of application of bisphosphonate locally on the amount of new bone has also been observed in other studies [9, 20, 40, 41] and are confirmed by some *in vitro* studies [19, 42-44]. However, it has not been shown *in vivo*. The declination in the amount of newly formed bone at the highest alendronate-group, compared to lower alendronate groups, might be explained by the toxicity of bisphosphonates on bone tissue. At a high dose, bisphosphonates have been shown to be toxic to osteoblasts [44, 45]. Another explanation might be the lack of space in the bone conduction chamber. The necrotic bone is not resorbed and therefore, no room is left for the formation of new bone.

We chose cefazolin as antibiotic. This is the antibiotic of first choice for orthopaedic surgery in The Netherlands. According to Edin et al. [36] local levels of cefazolin 200µg/mL decrease cell replication, but levels of 100µg/mL do not affect the replication of osteoblasts. The amount of cefazolin used in this study is well above the MIC for *S. Epidermidis*, and did not affect bone remodelling since no differences between the control group and the allograft group impregnated with cefazolin could be observed between for % graft bone volume or % new bone volume. However, since our study was powered to show differences, not equality, this result should be interpreted cautiously. Taking into account the half-life

of cefazolin, it will stay above MIC – and be effective – for at least 8 to 10 hours which is enough for prophylaxis. Cefazolin is completely eluted from the bone chips after three days. No subinhibitory amount of the drug is left behind which can induce resistances and therefore, cefazolin is an attractive choice for local prophylaxis [29].

No effect of the addition of DMB to allograft bone has been found in this study. In addition, histology shows similar resorption characteristics for DBM and allograft groups. The release of growth factors by osteoclastic resorption of allograft bone or DBM is probably quite similar. In addition, when combining DBM, alendronate and allograft bone, no additional bone was formed. Our results confirm several studies [46, 47], although other studies did find an enhancing effect of DBM on bone formation [48, 49]. Bae et al. [50] studied different DBM products and found a higher variability in concentration of bone morphogenic proteins among three different lots of the same DBM than among the different DBM products of different companies. Although our study pooled DBM of two goats (and therefore pooled two different lots), we did not find any effect of the addition of DBM to allograft bone.

Before implantation of the bone chamber we impacted the allograft bone to simulate the clinical situation as much as possible. However, caution should be taken when extrapolating the results. This bone chamber model in goats is un-loaded and therefore quite different from the loaded conditions as in a clinical situation. Also, no cement has been applied, as is done in a cemented revision hip arthroplasty with bone impaction grafting. In addition, a limitation of this study is the lack of biomechanical testing that would determine whether the groups treated with alendronate would be structurally stronger than the control group.

Basic principle of bone impaction grafting is that osteoclasts will resorb bone and osteoblasts will form new woven bone. Micromotions during normal gait cycles induce a rapid osteoclastic response. This too fast bone resorption might lead to initial instability of the implant, periprosthetic osteolysis and later implant migration [6, 7, 11, 51]. Local application of bisphosphonates has a clear influence on the osteoclastic activity, but little is known of the effect on implant migration and the occurrence of micromotions surrounding the implant.



## Conclusions

In conclusion, a dose-response relationship for local application of alendronate with respect to graft resorption has been shown in this study. The area of new bone in our experiment was optimal at 1 mg/mL alendronate. At this concentration, the amount of new bone was significantly higher compared to control and also when compared to lower (0.5 mg/mL) and higher alendronate concentrations (2 mg/mL). Local application of cefazolin (200 µg/mL) had neither effect on bone formation nor on bone graft resorption. Therefore, cefazolin at this concentration might be used as a prophylaxis against infection. The addition of DBM did not enlarge the new bone area.

## REFERENCES

1. Putzier M, Strube P, Funk JF, Gross C, Monig HJ, Perka C, Pruss A: **Allogenic versus autologous cancellous bone in lumbar segmental spondylodesis: a randomized prospective study.** *Eur Spine J* 2009, **18**(5):687-695.
2. Abdeen A, Healey JH: **Allograft-prosthesis composite reconstruction of the proximal part of the humerus: surgical technique.** *J Bone Joint Surg Am* 2010, **92 Suppl 1 Pt 2**:188-196.
3. Slooff TJ, Huiskes R, van Horn J, Lemmens AJ: **Bone grafting in total hip replacement for acetabular protrusion.** *Acta Orthop Scand* 1984, **55**(6):593-596.
4. Gie GA, Linder L, Ling RS, Simon JP, Slooff TJ, Timperley AJ: **Impacted cancellous allografts and cement for revision total hip arthroplasty.** *J Bone Joint Surg Br* 1993, **75**(1):14-21.
5. Schreurs BW, Slooff TJ, Buma P, Gardeniers JW, Huiskes R: **Acetabular reconstruction with impacted morsellised cancellous bone graft and cement. A 10- to 15-year follow-up of 60 revision arthroplasties.** *J Bone Joint Surg Br* 1998, **80**(3):391-395.
6. Ganz R, Perren SM, Ruter A: **[Mechanical induction of bone resorption].** *Fortschr Kiefer Gesichtschir* 1975, **19**:45-48.
7. Stadelmann VA, Terrier A, Pioletti DP: **Microstimulation at the bone-implant interface upregulates osteoclast activation pathways.** *Bone* 2008, **42**(2):358-364.
8. Karrholm J, Borssen B, Lowenhielm G, Snorrason F: **Does early micromotion of femoral stem prostheses matter? 4-7-year stereoradiographic follow-up of 84 cemented prostheses.** *J Bone Joint Surg Br* 1994, **76**(6):912-917.
9. Aspenberg P, Astrand J: **Bone allografts pretreated with a bisphosphonate are not resorbed.** *Acta Orthop Scand* 2002, **73**(1):20-23.
10. Rogers MJ, Gordon S, Benford HL, Coxon FP, Luckman SP, Monkkonen J, Frith JC: **Cellular and molecular mechanisms of action of bisphosphonates.** *Cancer* 2000, **88**(12 Suppl):2961-2978.



11. Stadelmann VA, Gauthier O, Terrier A, Bouler JM, Pioletti DP: **Implants delivering bisphosphonate locally increase periprosthetic bone density in an osteoporotic sheep model. A pilot study.** *Eur Cell Mater* 2008, **16**:10-16.
12. Kesteris U, Aspenberg P: **Rinsing morcellised bone grafts with bisphosphonate solution prevents their resorption. A prospective randomised double-blinded study.** *J Bone Joint Surg Br* 2006, **88**(8):993-996.
13. Astrand J, Aspenberg P: **Reduction of instability-induced bone resorption using bisphosphonates: high doses are needed in rats.** *Acta Orthop Scand* 2002, **73**(1):24-30.
14. Jakobsen T, Baas J, Kold S, Bechtold JE, Elmengaard B, Soballe K: **Local bisphosphonate treatment increases fixation of hydroxyapatite-coated implants inserted with bone compaction.** *J Orthop Res* 2009, **27**(2):189-194.
15. Jakobsen T, Baas J, Bechtold JE, Elmengaard B, Soballe K: **Soaking morselized allograft in bisphosphonate can impair implant fixation.** *Clin Orthop Relat Res* 2007, **463**:195-201.
16. Baas J, Elmengaard B, Jensen TB, Jakobsen T, Andersen NT, Soballe K: **The effect of pretreating morselized allograft bone with rhBMP-2 and/or pamidronate on the fixation of porous Ti and HA-coated implants.** *Biomaterials* 2008, **29**(19):2915-2922.
17. Agholme F, Aspenberg P: **Experimental results of combining bisphosphonates with allograft in a rat model.** *J Bone Joint Surg Br* 2009, **91**(5):670-675.
18. von Knoch F, Jaquier C, Kowalsky M, Schaeren S, Alabre C, Martin I, Rubash HE, Shanbhag AS: **Effects of bisphosphonates on proliferation and osteoblast differentiation of human bone marrow stromal cells.** *Biomaterials* 2005, **26**(34):6941-6949.
19. Ozturk AM, Tabak AY, Aktekin CN, Altay M, Erdemli E, Karahuseyinoglu S, Korkusuz F: **Alendronate enhances antibiotic-impregnated bone grafts in the treatment of osteomyelitis.** *Int Orthop* 2008, **32**(6):821-827.
20. Jakobsen T, Baas J, Bechtold JE, Elmengaard B, Soballe K: **The effect of soaking allograft in bisphosphonate: a pilot dose-response study.** *Clin Orthop Relat Res* 2010, **468**(3):867-874.
21. Watson JT: **Overview of biologics.** *J Orthop Trauma* 2005, **19**(10 Suppl):S14-16.
22. Wildemann B, Kadow-Romacker A, Haas NP, Schmidmaier G: **Quantification of various growth factors in different demineralized bone matrix preparations.** *J Biomed Mater Res A* 2007, **81**(2):437-442.
23. Shih HN, Shih LY, Sung TH, Chang YC: **Restoration of bone defect and enhancement of bone ingrowth using partially demineralized bone matrix and marrow stromal cells.** *J Orthop Res* 2005, **23**(6):1293-1299.
24. Isefuku S, Joyner CJ, Simpson AH: **Gentamicin may have an adverse effect on osteogenesis.** *J Orthop Trauma* 2003, **17**(3):212-216.
25. Gristina AG, Costerton JW: **Bacterial adherence to biomaterials and tissue. The significance of its role in clinical sepsis.** *J Bone Joint Surg Am* 1985, **67**(2):264-273.
26. Witso E, Persen L, Benum P, Bergh K: **Release of netilmicin and vancomycin from cancellous bone.** *Acta Orthop Scand* 2002, **73**(2):199-205.

27. Witso E, Persen L, Benum P, Aamodt A, Husby OS, Bergh K: **High local concentrations without systemic adverse effects after impaction of netilmicin-impregnated bone.** *Acta Orthop Scand* 2004, **75**(3):339-346.
28. Winkler H, Janata O, Berger C, Wein W, Georgopoulos A: **In vitro release of vancomycin and tobramycin from impregnated human and bovine bone grafts.** *J Antimicrob Chemother* 2000, **46**(3):423-428.
29. Witso E, Persen L, Loseth K, Benum P, Bergh K: **Cancellous bone as an antibiotic carrier.** *Acta Orthop Scand* 2000, **71**(1):80-84.
30. Witso E, Persen L, Benum P, Bergh K: **Cortical allograft as a vehicle for antibiotic delivery.** *Acta Orthop* 2005, **76**(4):481-486.
31. Buttaro MA, Gimenez MI, Greco G, Barcan L, Piccaluga F: **High active local levels of vancomycin without nephrotoxicity released from impacted bone allografts in 20 revision hip arthroplasties.** *Acta Orthop* 2005, **76**(3):336-340.
32. Buttaro MA, Gonzalez Della Valle AM, Pineiro L, Mocetti E, Morandi AA, Piccaluga F: **Incorporation of vancomycin-supplemented bone incorporation of vancomycin-supplemented bone allografts: radiographical, histopathological and immunohistochemical study in pigs.** *Acta Orthop Scand* 2003, **74**(5):505-513.
33. Aspenberg P, Wang, J.S.: **A new bone chamber used for measuring osteoconduction in rats.** *Eur J Exp Musculoskel Res* 1993(2):69-74.
34. van der Donk S, Buma P, Aspenberg P, Schreurs BW: **Similarity of bone ingrowth in rats and goats: a bone chamber study.** *Comp Med* 2001, **51**(4):336-340.
35. Mathijssen NM, Petit PL, Pilot P, Schreurs BW, Buma P, Bloem RM: **Impregnation of bone chips with antibiotics and storage of antibiotics at different temperatures: an in vitro study.** *BMC Musculoskelet Disord* 2010, **11**:96.
36. Edin ML, Micalu T, Lester GE, Lindsey RW, Dahners LE: **Effect of cefazolin and vancomycin on osteoblasts in vitro.** *Clin Orthop Relat Res* 1996(333):245-251.
37. Tagil M, Aspenberg P: **Impaction of cancellous bone grafts impairs osteoconduction in titanium chambers.** *Clin Orthop Relat Res* 1998(352):231-238.
38. Fleisch H: **Bisphosphonates: mechanisms of action.** *Endocr Rev* 1998, **19**(1):80-100.
39. Bone HG, Hosking D, Devogelaer JP, Tucci JR, Emkey RD, Tonino RP, Rodriguez-Portales JA, Downs RW, Gupta J, Santora AC *et al*: **Ten years' experience with alendronate for osteoporosis in postmenopausal women.** *N Engl J Med* 2004, **350**(12):1189-1199.
40. Astrand J, Aspenberg P: **Systemic alendronate prevents resorption of necrotic bone during revascularization. A bone chamber study in rats.** *BMC Musculoskelet Disord* 2002, **3**:19.
41. Jakobsen T, Kold S, Bechtold JE, Elmengaard B, Soballe K: **Local alendronate increases fixation of implants inserted with bone compaction: 12-week canine study.** *J Orthop Res* 2007, **25**(4):432-441.
42. Im GI, Qureshi SA, Kenney J, Rubash HE, Shanbhag AS: **Osteoblast proliferation and maturation by bisphosphonates.** *Biomaterials* 2004, **25**(18):4105-4115.

43. Reinholz GG, Getz B, Pederson L, Sanders ES, Subramaniam M, Ingle JN, Spelsberg TC: **Bisphosphonates directly regulate cell proliferation, differentiation, and gene expression in human osteoblasts.** *Cancer Res* 2000, **60**(21):6001-6007.
44. Gangoiti MV, Cortizo AM, Arnol V, Felice JI, McCarthy AD: **Opposing effects of bisphosphonates and advanced glycation end-products on osteoblastic cells.** *Eur J Pharmacol* 2008, **600**(1-3):140-147.
45. Orriss IR, Key ML, Colston KW, Arnett TR: **Inhibition of osteoblast function in vitro by aminobisphosphonates.** *J Cell Biochem* 2009, **106**(1):109-118.
46. Becker W, Urist MR, Tucker LM, Becker BE, Ochsenbein C: **Human demineralized freeze-dried bone: inadequate induced bone formation in athymic mice. A preliminary report.** *J Periodontol* 1995, **66**(9):822-828.
47. Intini G, Andreana S, Buhite RJ, Bobek LA: **A comparative analysis of bone formation induced by human demineralized freeze-dried bone and enamel matrix derivative in rat calvaria critical-size bone defects.** *J Periodontol* 2008, **79**(7):1217-1224.
48. Schwartz Z, Mellonig JT, Carnes DL, Jr., de la Fontaine J, Cochran DL, Dean DD, Boyan BD: **Ability of commercial demineralized freeze-dried bone allograft to induce new bone formation.** *J Periodontol* 1996, **67**(9):918-926.
49. Schwartz Z, Somers A, Mellonig JT, Carnes DL, Jr., Dean DD, Cochran DL, Boyan BD: **Ability of commercial demineralized freeze-dried bone allograft to induce new bone formation is dependent on donor age but not gender.** *J Periodontol* 1998, **69**(4):470-478.
50. Bae HW, Zhao L, Kanim LE, Wong P, Delamarter RB, Dawson EG: **Intervariability and intravariability of bone morphogenetic proteins in commercially available demineralized bone matrix products.** *Spine (Phila Pa 1976)* 2006, **31**(12):1299-1306; discussion 1307-1298.
51. Hilding M, Ryd L, Toksvig-Larsen S, Aspenberg P: **Clodronate prevents prosthetic migration: a randomized radiostereometric study of 50 total knee patients.** *Acta Orthop Scand* 2000, **71**(6):553-557.



## CHAPTER 4

# COMPARISON OF CONTAMINATION OF FEMORAL HEADS AND PRE-PROCESSED BONE CHIPS DURING HIP REVISION ARTHROPLASTY

Nina M.C. Mathijssen, Patrick D. Sturm, Peter Pilot, Rolf M. Bloem,  
Pieter Buma, Pieter L.C. Petit, B. Willem Schreurs BW.

(Cell Tissue Bank. 2013 Jan 29)

[Epub ahead of print]

## ABSTRACT

**Introduction:** With bone impaction grafting, cancellous bone chips made from allograft femoral heads are impacted in a bone defect, which introduces an additional source of infection. The potential benefit of the use of preprocessed bone chips was investigated by comparing the bacterial contamination of bone chips prepared intraoperatively with the bacterial contamination of pre-processed bone chips at different stages in the surgical procedure.

**Methods:** To investigate baseline contamination of the bone grafts, specimens were collected during 88 procedures before actual use or preparation of the bone chips: in 44 procedures intraoperatively prepared chips were used (Group A) and in the other 44 procedures pre-processed bone chips were used (group B). In 64 of these procedures (32 using locally prepared bone chips and 32 using pre-processed bone chips) specimens were also collected later in the procedure to investigate contamination after use and preparation of the bone chips.

**Results:** In total, 8 procedures had one or more positive specimen(s) (12.5%). Contamination rates were not significantly different between bone chips prepared at the operating theatre and pre-processed bone chips.

**Conclusion:** In conclusion, there was no difference in bacterial contamination between bone chips prepared from whole femoral heads in the operating room and pre-processed bone chips, and therefore, both types of bone allografts are comparable with respect to risk of infection.

## INTRODUCTION

Total hip arthroplasty (THA) is one of the most successful medical procedures performed in an elderly population suffering from crippling osteoarthritis [1]. The number of THAs is expected to increase due to the ageing population, but also because hip prostheses are placed in patients who were formerly seen as too sick. Unfortunately, approximately 12% of these implants will fail in time and these patients will need hip revision surgery [1]. During hip revision surgery, bone impaction grafting (BIG) is a frequently used technique for reconstruction of bone defects [2-4]. With BIG, cancellous bone chips made from allograft femoral heads are impacted in the defect. However, the use of BIG introduces a potential source of infection. Prosthesis infection may occur post-operatively, but is often caused by bacterial contamination intra-operatively. Relatively small numbers of bacteria of low virulence are able to establish infection in the presence of the surgical implant and an abnormal functioning immune system [5-8].

The processing of femoral heads to obtain bone chips can be done in the laboratory of a bone bank or in the operating theatre during surgery just prior to use. As compared to bone chips prepared in the laboratory, we hypothesised that bone chips prepared intraoperatively may pose an additional risk for infection; the preparation of bone chips in the operation room takes about ten minutes, it necessitates the use of special instruments in the presence of all surgical team members, and due to the limited area in a down flow plenum system the preparation of bone chips often takes place outside the plenum. In contrast, preprocessed bone chips are prepared in a top-class level clean room with optimal controlled environmental conditions and no surgery time is needed for preparation. Also, during the process, specimens are collected to control for contamination and bone chips with positive bacterial cultures are discarded.

The potential benefit of the use of preprocessed bone chips was investigated by comparing the bacterial contamination of bone chips prepared intraoperatively with the bacterial contamination of pre-processed bone chips at different stages in the surgical procedure.

## METHODS

### Patients

Consecutive patients on the waiting list for hip revision surgery were included. All surgeries were performed at Reinier de Graaf Groep, Delft and at Radboud University Medical Centre Nijmegen, both in The Netherlands. The study was approved by the Medical Ethics Committee. Written informed consent was obtained from all patients.

To investigate baseline contamination of the bone grafts, specimens were collected during 88 procedures before actual use or preparation of the bone chips: in 44 procedures intraoperatively prepared chips were used (Group A) and in the other 44 procedures pre-processed bone chips were used (group B). Patients were randomly assigned to group A or B. In 64 of these procedures (32 using locally prepared bone chips and 32 using pre-processed bone chips) specimens were also collected later in the procedure to investigate contamination after preparation and impaction of the bone chips.

Sample size calculation was based on the results of several studies on contamination of allograft femoral heads just prior to implantation [9-14]. Based on these studies, the minimal relevant difference was set to 7% and we assumed the standard deviation on the relative change to be 10%. Two sided  $\alpha$  and  $\beta$  were set to be 5% and 10% respectively.

### Bone grafts

Allograft femoral heads were obtained from the bonebank of Sanquin, Nijmegen, or from Bislife, Leiden, both in The Netherlands. At the operating theater, the femoral head was thawed with warm saline for 15 minutes and then morselized with a bone mill (Novio Magus bone mill, Spierings Medical Technology, Nijmegen, The Netherlands).

Pre-processed bone chips were obtained from the bonebank of Sanquin, Nijmegen, The Netherlands. For the preparation of pre-processed bone chips, femoral heads were morselized under clean room conditions with a bone mill (Novio Magus bone mill, Spierings Medical Technology, Nijmegen, The Netherlands). Bone chips were then rinsed with sterile normal saline five times and placed in a sterile container and frozen at  $-80^{\circ}\text{C}$ . Sterility tests were performed throughout the process; bone chips with a positive culture were discarded. At the operating theater, chips were thawed with warm saline for 10 minutes.



## Specimen collection

Specimens for bacterial culture were collected during the surgical procedure at four predefined time points: 1) after unpacking the bone 2) after thawing the bone 3) after morselizing the bone in the operating theatre, and in case of pre-processed bone chips after opening the container of the chips to take out bone chips 4) after finishing the impaction grafting procedure from the already impacted bone chips, just before cementation. The additional specimens for investigation of the baseline contamination were collected at time point 1 and 2.

Specimens were collected by one of the investigators (NM) in a standardized way using sterile single packed cotton wool tipped swabs (Peha Wattestbchen, Paul Hartmann AG, Heidenheim, Germany). The bone surface was wiped down using 2 swabs held together until most of the bone area was swabbed, which was determined visually. At each predefined moment, a negative control was collected by holding 2 swabs together above the bone surface without collection of material.

In the operation room, immediately after collection, the specimens and negative swab controls were placed in 10 mL of a thioglycolate broth (Oxoid supplemented with vitamin K1, hemin and E4 solution, Reinier de Graaf Hospital, Delft, The Netherlands).

## Culture

After all materials for culture were collected, these were transported to the laboratory. Upon arrival the inoculated liquid broth media were directly incubated. Incubation was in 37°C for 5 days with subcultures performed after 2 days of incubation and at the end of incubation. Subcultures were performed using 2 sheep blood agars (Becton Dickinson), which were incubated for 48 hours at 37°C in 5% CO<sub>2</sub> and under anaerobic conditions. Growth on the solid media was identified by matrix-assisted laser desorption ionization–time of flight mass spectrometry (MALDI-TOF MS) using the Bruker Microflex LT with Biotyper version 3.0 (Bruker Daltonik GmbH, Leipzig, Germany).

## Air quality control of operation room

To control for differences in air quality as a potential cause of differences in contamination rates of the bone grafts detected, the environmental circumstances in the operating room were monitored during each surgery by measuring the amount of particles and colony forming units (CFUs) in the air.

Measurements of the amount of particles in the air were done with an Airborne Particle Counter (APC Plus, Kregliner Europe, Antwerp, Belgium), every 10 minutes for 1 minute during the surgery at a distance of approximately 1.5 m of the wound.

The microbiological quality of the air was measured 4 times during surgery: directly after incision, directly after opening of the container of the femoral head or the opening of the container of the pre-processed bone chips, at the time the bone graft was first used in the procedure, and again 10 minutes later. At a distance of approximately 1.5 m of the wound, 200 l of air with an airflow rate of 100 l/min was aspirated with a High Flow microbial Airborne Sampler (RCS High Flow, Kregliner Europe, Antwerp, Belgium) containing an RCS-strip with Tryptic Soy Agar (TSA, Kregliner Europe, Antwerp, Belgium). A sedimentation plate (TSA, Kregliner Europe, Antwerp, Belgium) was positioned on the instrument table where the bone chips were prepared at the moment of opening the container of the allograft bone for one hour. The number of CFUs on the sedimentation plate as well as on the RCS-strips was counted after 48 h of incubation at 30 °C and CFUs/m<sup>3</sup> was calculated.

## Follow-up

The medical files were reviewed, including clinical, radiological, and laboratory findings, to assess the occurrence of an infection post-operatively.

## Statistics

Chi Square test was performed to compare contamination of the intraoperatively prepared and the pre-processed bone chips, as well as the contamination of the negative control swabs. Air quality during the surgical procedures was investigated using the Mann Whitney U test. All statistical analyses were performed using PASW statistics 18.0. Differences were considered to be significant at  $p < 0.05$ .

## RESULTS

In 88 procedures, baseline contamination of the allograft bone was determined by collecting specimens at time points 1 and 2. Positive specimens were present in 5 procedures (5.7%). In 64 procedures, specimens were also collected at later time points. In total, 8 procedures had one or more positive specimen (12.5%). Four procedures had

positive culture results at more than one time point. In one of these, a second bacterial species was cultured. Culture results are summarized in Table 4.1.

Contamination rates were not significantly different between bone chips prepared at the operating theatre and pre-processed bone chips. In 4 out of the 8 procedures with one or more positive specimen, femoral heads were used and in 4 procedures pre-processed bone chips were used. Also, when the total amount of contaminated specimens are compared, no significant differences could be found; 2.6% contamination of the chips prepared at the operating theatre and 5.3% contamination of the pre-processed bone chips ( $p=0.236$ ). In total 3.9% of all bone cultures was positive.

Of the negative control cultures 6.5% was positive. No significant differences could be found between the bone cultures and the negative control cultures ( $p=0.674$ ). 12 control cultures from 11 procedures were positive. In 5 procedures, identical bacteria were recovered in the negative control swabs and in one or more of the bone specimens (Table 4.1). In 5 procedures a single negative swab was culture positive with CoNS (*S. hominis* ( $n=2$ ), *S. warneri* ( $n=2$ ), *S. epidermidis* ( $n=1$ ), *S. pasteurii* ( $n=1$ ), *Staphylococcus spp.*) and in one procedure with *Micrococcus spp.*

Air quality, defined by the amount of particles in the air, the microbiological quality of the air in the operating room ( $CFU/m^3$ ) and by the sedimentation plates on the instrument

**Table 4.1** Positive bone culture results

Procedure	Bone culture (positive culture/total amount of cultures)	Microorganism	Negative control (positive culture/total amount of cultures)	Microorganism
1	2/4	PA	1/4	PA
2	1/4	CoNS	1/4	CoNS
3	1/4	MS	-	-
4	2/4	SW	1/4	SW
5	2/4	KS/CS	-	-
6	1/4	CS	-	-
7	3/4	RE	1/4	RE
8	1/4	SE	1/4	SE

Eight procedures with positive bone cultures. PA=*propionibacterium acnes*, CoNS=coagulase negative *Staphylococcus*, MS=*Moraxella spp.*, SW=*Staphylococcus Warneri*, KS=*Kocuria spp.*, CS=*Corynebacterium spp.*, RE=*Rhodococcus Erythropolis*, SE=*Staphylococcus Epidermidis*.

**Table 4.2** Air quality results of hip revision surgeries

	Group A	Group B	p-value
CFU/m <sup>3</sup>	84 ± 93	64 ± 64	0.302
CFU/hour/m <sup>2</sup>	2521 ± 4452	1991 ± 4004	0.640
Particles 0.3 µm	6995 ± 8214	3835 ± 3923	0.474
Particles 0.5 µm	655 ± 893	406 ± 493	0.440
Particles 1.0 µm	82 ± 92	52 ± 44	0.262
Particles 5.0 µm	4.4 ± 2.6	4.2 ± 2.8	0.546

Air quality results ( $\pm$ SD) of hip revision surgeries in which femoral heads were used versus hip revision surgeries in which preprocessed bone chips were used. Group A=femoral heads used during procedure, Group B=pre-processed bone chips used during procedure.

tables (CFU/m<sup>2</sup>), was not significantly different during the procedures in group A and group B. Results are presented in Table 4.2.

Mean follow-up of the 8 patients with one or more positive bone cultures was 23 months ( $\pm$ 7). Two of these patients developed an infection, however, in none of these patients the infection was caused by the bacteria isolated from the cultures at implantation.

## DISCUSSION

It was hypothesized that during hip revision surgery with bone impaction grafting, culture specimens of femoral heads would be more contaminated compared to culture specimens of pre-processed bone chips, since these chips are prepared under more controlled environmental conditions. However, our results revealed no significant differences; culture positivity of specimens collected during hip revision surgery was similar in chips prepared at the operating room and in pre-processed bone chips. Air quality was measured during each procedure using a standardized protocol and could not account for these findings. The measured bacterial and particle counts during procedures using either bone chips prepared in the operating room or using pre-processed bone chips were comparable. In addition there was no quantitative correlation between air quality and positive cultures.

The overall culture positive rate of the bone allografts was 3.9% and is within the range of 3.4% to 12% that has been reported previously [9, 15-17]. This range of reported culture positivity may be caused by differences in specimen collection methods and culture

methods. Sommerville et al. [15] showed increased culture positive rates with increased numbers of specimens and showed that surface swabs had low sensitivity as compared to bone and tissue biopsy. However, their method of swabbing was not described. Contrary, others argue that local tissue biopsies lack sensitivity and that swabbing the complete surface of the bone will detect most contamination since contamination of the living donor allograft is superficial and not evenly distributed on the graft [18]. Our study further shows that positive culture findings are not consistent when consecutive specimens are collected, despite swabbing of the whole surface. These inconsistent findings may reflect the very low numbers of contaminating bacteria that are present at baseline or later during the processing and use. At time point one, before thawing the bone, all cultures were negative, which may indicate that specimen collection from frozen bone is inadequate. The higher number of positive specimens collected at later time points could also reflect contamination of the allograft during manipulations in the operating room where there are always low numbers of bacteria present in the air as well as in the wound area [10, 19].

Most of the bacterial species that were recovered were typical skin bacteria including *Staphylococcus spp.*, *Corynebacterium spp.*, and *P. acnes*, while *R. erythropolis*, *Kocuria spp.*, *Micrococcus spp.*, and *Moraxella spp.* have been described as environmental bacteria. Most of these bacteria have been described as contaminants of bone allografts as well as contaminants of the surgical wound area and these results are in accordance with other studies. At the same time, intraoperative contamination of the prosthesis is considered to be the main cause of late prosthesis infections, and most of these bacterial species have been implicated in orthopedic prosthesis infection.

Not much research has been done on contamination of bone allograft at implantation [9]. The clinical significance of these positive culture findings has been discussed earlier. In most patients positive culture findings of bone grafts were not related to late infections. In the current study, two of the eight patients with positive bone graft cultures, developed infection after a minimum follow-up of 23 months. However, in none of these patients the infection was caused by the bacteria isolated from the cultures at implantation.

Since liquid broth culture media are susceptible to contamination of the culture system, positive cultures may not reflect true contamination of the bone allografts but may represent contamination that may occur during specimen collection, inoculation, or handling in the laboratory. Indeed, 12 of the 304 negative control swabs were culture positive. However, in 13 positive cultures including 4 negative control swabs, laboratory contamination was excluded because cultures became positive without handling in the

laboratory and thus must represent bacteria collected in the operating room either from the allograft bone material or from the direct environment.

Pre-processed bone chips have the advantage of being more rapidly ready for use during surgery. The time advantage is estimated to be 10 to 15 min, although it could not be quantified in this study since most often, pre-processed chips were used in combination with whole femoral heads. In addition, since pre-processed bone chips are more thoroughly cleaned by rinsing the chips 5 times with saline and thereby washing cells and tissues out of the graft and reducing the immunological reaction, there may be a better incorporation of the allograft bone after bone impaction grafting [20]. On the other hand, a disadvantage of pre-processed bone chips may be the higher costs compared to unprocessed femoral heads. However, when considering the costs of a bone mill including the costs for sterilization and the time investment of the surgical team when preparing bone chips from femoral heads, bone chips prepared at the bone bank may actually be less expensive.

In conclusion, there was no difference in bacterial contamination of the allografts at baseline or during the surgical procedure between bone chips prepared from whole femoral heads in the operating room and pre-processed bone chips, and therefore, both types of bone allografts are comparable with respect to risk of infection. In the choice between pre-processed bone chips and preparation of bone chips in the operating room, other factors, such as time advantage, ease of use, and costs, must be considered.

## REFERENCES

1. Labek G, Thaler M, Janda W, Agreiter M, Stockl B: **Revision rates after total joint replacement: cumulative results from worldwide joint register datasets.** *J Bone Joint Surg Br* 2011, **93**(3):293-297.
2. Slooff TJ, Huiskes R, van Horn J, Lemmens AJ: **Bone grafting in total hip replacement for acetabular protrusion.** *Acta Orthop Scand* 1984, **55**(6):593-596.
3. Gie GA, Linder L, Ling RS, Simon JP, Slooff TJ, Timperley AJ: **Impacted cancellous allografts and cement for revision total hip arthroplasty.** *J Bone Joint Surg Br* 1993, **75**(1):14-21.
4. Schreurs BW, Slooff TJ, Buma P, Gardeniers JW, Huiskes R: **Acetabular reconstruction with impacted morsellised cancellous bone graft and cement. A 10- to 15-year follow-up of 60 revision arthroplasties.** *J Bone Joint Surg Br* 1998, **80**(3):391-395.
5. Mahomed NN, Barrett JA, Katz JN, Phillips CB, Losina E, Lew RA, Guadagnoli E, Harris WH, Poss R, Baron JA: **Rates and outcomes of primary and revision total hip replacement in the United States medicare population.** *J Bone Joint Surg Am* 2003, **85-A**(1):27-32.

6. Zhan C, Kaczmarek R, Loyo-Berrios N, Sangl J, Bright RA: **Incidence and short-term outcomes of primary and revision hip replacement in the United States.** *J Bone Joint Surg Am* 2007, **89**(3):526-533.
7. Ridgeway S, Wilson J, Charlet A, Kafatos G, Pearson A, Coello R: **Infection of the surgical site after arthroplasty of the hip.** *J Bone Joint Surg Br* 2005, **87**(6):844-850.
8. Gristina AG, Costerton JW: **Bacterial adherence to biomaterials and tissue. The significance of its role in clinical sepsis.** *J Bone Joint Surg Am* 1985, **67**(2):264-273.
9. van de Pol GJ, Sturm PD, van Loon CJ, Verhagen C, Schreurs BW: **Microbiological cultures of allografts of the femoral head just before transplantation.** *J Bone Joint Surg Br* 2007, **89**(9):1225-1228.
10. Knobben BA, Engelsma Y, Neut D, van der Mei HC, Busscher HJ, van Horn JR: **Intraoperative contamination influences wound discharge and periprosthetic infection.** *Clin Orthop Relat Res* 2006, **452**:236-241.
11. Clarke MT, Lee PT, Roberts CP, Gray J, Keene GS, Rushton N: **Contamination of primary total hip replacements in standard and ultra-clean operating theaters detected by the polymerase chain reaction.** *Acta Orthop Scand* 2004, **75**(5):544-548.
12. Maathuis PG, Neut D, Busscher HJ, van der Mei HC, van Horn JR: **Perioperative contamination in primary total hip arthroplasty.** *Clin Orthop Relat Res* 2005(433):136-139.
13. Byrne AM, Morris S, McCarthy T, Quinlan W, O'Byrne J M: **Outcome following deep wound contamination in cemented arthroplasty.** *Int Orthop* 2007, **31**(1):27-31.
14. Davis N, Curry A, Gambhir AK, Panigrahi H, Walker CR, Wilkins EG, Worsley MA, Kay PR: **Intraoperative bacterial contamination in operations for joint replacement.** *J Bone Joint Surg Br* 1999, **81**(5):886-889.
15. Sommerville SM, Johnson N, Bryce SL, Journeaux SF, Morgan DA: **Contamination of banked femoral head allograft: incidence, bacteriology and donor follow up.** *Aust N Z J Surg* 2000, **70**(7):480-484.
16. Ivory JP, Thomas IH: **Audit of a bone bank.** *J Bone Joint Surg Br* 1993, **75**(3):355-357.
17. Chiu CK, Lau PY, Chan SW, Fong CM, Sun LK: **Microbial contamination of femoral head allografts.** *Hong Kong Med J* 2004, **10**(6):401-405.
18. Vehmeyer SB, Slooff AR, Bloem RM, Petit PL: **Bacterial contamination of femoral head allografts from living donors.** *Acta Orthop Scand* 2002, **73**(2):165-169.
19. Whyte W, Hodgson R, Tinkler J: **The importance of airborne bacterial contamination of wounds.** *J Hosp Infect* 1982, **3**(2):123-135.
20. van der Donk S, Weernink T, Buma P, Aspenberg P, Slooff TJ, Schreurs BW: **Rinsing morselized allografts improves bone and tissue ingrowth.** *Clin Orthop Relat Res* 2003(408):302-310.





## CHAPTER 5

# IMPREGNATION OF BONE CHIPS WITH **ANTIBIOTICS** AND STORAGE OF ANTIBIOTICS AT DIFFERENT TEMPERATURES: *AN IN VITRO STUDY*

Nina M.C. Mathijssen, Pieter L.C. Petit, Peter Pilot, B. Willem Schreurs, Pieter Buma, Rolf M. Bloem.

(BMC Musculoskelet Disord. 2010 May 25;11:96.)

Doi: 10.1186/1471-2474-11-96

## ABSTRACT

**Background:** Allograft bone used in joint replacement surgery can additionally serve as a carrier for antibiotics and serve as a prophylaxis against infections. However, *in vitro* dose-response curves for bone chips impregnated with different kinds of antibiotics are not available. In addition, while it would be desirable to add the antibiotics to allograft bone chips before these are stored in a bone bank, the effects of different storage temperatures on antibiotics are unknown.

**Methods:** Five different antibiotics (cefazolin, clindamycin, linezolid, oxacillin, vancomycin) were stored, both as pills and as solutions, at  $-80^{\circ}\text{C}$ ,  $-20^{\circ}\text{C}$ ,  $4^{\circ}\text{C}$ ,  $20^{\circ}\text{C}$  and  $37^{\circ}\text{C}$ ; in addition, bone chips impregnated with cefazolin and vancomycin were stored at  $-80^{\circ}\text{C}$  and  $-20^{\circ}\text{C}$ . After 1 month, 6 months and 1 year, the activity of the antibiotics against *Staphylococcus epidermidis* was measured using an inoculated agar. The diameter of the *S. epidermidis*-free zone was taken as a measure of antibiotic activity. In a separate experiment, *in vitro* dose-response curves were established for bone chips impregnated with cefazolin and vancomycin solutions at five different concentrations. Finally, the maximum absorbed amounts of cefazolin and vancomycin were established by impregnating 1 g of bone chips with 5 ml of antibiotic solution.

**Results:** A decrease of the *S. epidermidis*-free zone was seen with oxacillin and cefazolin solutions stored at  $37^{\circ}\text{C}$  for 1 month, with vancomycin stored at  $37^{\circ}\text{C}$  for 6 months and with cefazolin and oxacillin solutions stored at  $20^{\circ}\text{C}$  for 6 months. The activity of the other antibiotic solutions, pills and impregnated bone chips was not affected by storage. The *in vitro* dose-response curves show that the free-zone diameter increases logarithmically with antibiotic concentration. The absorbed antibiotic amount of one gram bone chips was determined.

**Conclusions:** Storage of antibiotics in frozen form or storage of antibiotic pills at temperatures up to  $37^{\circ}\text{C}$  for 12 months does not affect their activity. However, storage of antibiotic solutions at temperatures above  $20^{\circ}\text{C}$  does affect the activity of some of the antibiotics investigated. The *in vitro* dose-response curve can be used to determine the optimal concentration(s) for local application. It provides the opportunity to determine the antibiotic content of bone chips, and thus the amount of antibiotics available locally after application.

## BACKGROUND

Infection is one of the most devastating adverse events following joint replacement surgery. Deep infection rates in primary hip replacement surgery are around 0.5% to 2%. These infections result in a reduced quality of life [1, 2]. The patient often needs several re-operations, and if surgical debridement is not sufficient a Girdlestone situation is created; the patient then has to function without prosthesis for three to six months, which markedly limits physical activity. Furthermore, the hospitalisation costs for an infected patient are about 3.7 times those for a similar, uninfected patient [1].

Bone impaction grafting (BIG) for joint replacement surgery has been used with satisfactory results in clinical practice, for acetabular reconstructions since 1979 and for femoral reconstructions since 1987 [3-10]. With BIG, first the segmental bone defects in acetabulum and femur are restored with metal meshes. Next, these defects are filled with tightly impacted morselized cancellous bone chips in combination with a cemented prosthesis. Osteoclasts will resorb necrotic graft remnants and osteoblasts will form new woven bone. This remodelling of newly formed bone into its characteristic structure will lead to the biological repair of the defect following surgery [11].

Surgery with BIG is more complex and time-consuming than primary hip surgery which may contribute to a higher infection rate in hip revision surgery (percentages ranging from 2.0% to 2.5% [12-14]). BIG creates an avascular area where local circulation is disrupted. If infections arises, this may prevent antibiotics that are administered systemically to reach the infected bone [15]. In addition, the formation of a biofilm on the surface of the implant renders systemic antibiotics less effective [16].

Bone cements containing antibiotics were developed to solve this problem. These cements may serve as a drug delivery system and prophylaxis against infections as they make it possible to achieve higher local drug concentrations. However, controversy exists on the efficacy of the antibiotic-containing cements [17]. Probably 90% of the antibiotics contained in the cement is never released [18]. Only when cracks are formed in the cement layer will a small, sub-inhibitory amount of antibiotics be released into the surrounding tissue. This release can continue for years, potentially inducing resistance. [18].

Several studies have shown that morselized allograft bone, which is used not only in BIG but also in other surgeries, can be made to act as a carrier for antibiotics, either by impregnating the bone grafts with various antibiotic solutions [19-23], or by mixing them with antibiotic powders [24, 25]. Although these studies showed, *in vitro* as well

as *in vivo*, that bone impregnated with antibiotics can be used effectively as prophylaxis against infections, they did not establish the concentration of antibiotic present in the bone after impregnation and how much was released locally. Furthermore, no correlation of antibiotic concentration and zone of inhibition was reported of the antibiotics used in combination with bone chips. Finally, allograft bone is stored at a bone bank at  $-80^{\circ}\text{C}$ , then thawed in the operating room. In the impregnation studies, all the antibiotics were added to the thawed bone, immediately before use. It is thus unknown whether the antibiotics can be added before freezing without affecting their activity.

Based on this we investigated if storage of antibiotics and antibiotic-loaded bone grafts at different temperatures affects their activity. The correlation between antibiotic concentration and zones of inhibition for the bone/antibiotics composites was analysed. The results permit us to develop a standardized bone bank product in which the amount of antibiotics present on the bone chips, and therefore the amount of antibiotics released locally from the bone, will be known.

## METHODS

### Measurement of activities

For all tests performed in this study, the following method was used:

Antibiotic pills, antimicrobial susceptibility test disks (Oxoid) with antibiotic solution dripped onto the disks and bone chips impregnated with antibiotic solution were placed on an inoculated iso agar (cefazolin, clindamycin, linezolid or vancomycin) or an inoculated Mueller Hinton agar (oxacillin). Bone chips were placed in a hole of 10 mm diameter punched into, but not through, the agar and then covered with 25  $\mu\text{l}$  saline dripped onto them.

All agars were inoculated with 0.5 McFarland ATCC 12228 *Staphylococcus epidermidis* since this organism is one of the main pathogens colonizing biomaterials [26]. After storing the iso agars at  $37^{\circ}\text{C}$  and the Mueller Hinton agars at  $30^{\circ}\text{C}$  for 18–24 hours, the zones of inhibition were measured.

Antibiotic pills from the routine clinical lab were used as controls. The zone of inhibition of these pills is comparable to that of 10  $\mu\text{l}$  antibiotic solution and that of chips freshly impregnated with 10  $\mu\text{l}$  antibiotic solution.

Cefazolin, clindamycin, linezolid, oxacillin and vancomycin were used in this study, all antibiotics against gram stain positive micro-organisms, the main cause for orthopaedic infections. Oxacillin is the preferred treatment for systemic staphylococcal infections and in case of penicillin hypersensitivity the others are used (mainly cefazolin or clindamycin). For prophylaxis cefazolin or clindamycin are preferred and in case of infection with methicillin resistant *Staphylococcus aureus* (MRSA) vancomycin is used. In this way all important antibiotics against these gram stain positive micro-organisms were tested. The concentrations used for the tests are the concentrations used in the whole range of clinical situations: systemic or local infection and prophylactic use. In addition, high concentrations were used to determine local concentration limits.

Five different storage temperatures were used in the experiments.  $-80^{\circ}\text{C}$  and  $-20^{\circ}\text{C}$  are storage temperatures for allograft bone in bone banks.  $4^{\circ}\text{C}$  and  $20^{\circ}\text{C}$  are commonly used storage temperatures in the laboratory and  $20^{\circ}\text{C}$  is the temperature of the operation room.  $37^{\circ}\text{C}$  was included so as to investigate antibiotic stability at higher temperature and because this temperature is body temperature.

### **Storage of antibiotic pills**

Pills of five different antibiotics – cefazolin 60  $\mu\text{g}$ , clindamycin 25  $\mu\text{g}$ , linezolid 30  $\mu\text{g}$ , oxacillin 1  $\mu\text{g}$  and vancomycin 70  $\mu\text{g}$  – were stored at five different temperatures. For each antibiotic, nine pills of each antibiotic were stored in a closed tube at each temperature. After 1 month, 6 months and 1 year of storage, three pills of each antibiotic were brought to room temperature and placed on an agar to determine the inhibition zone of the pills.

### **Storage of antibiotic solutions**

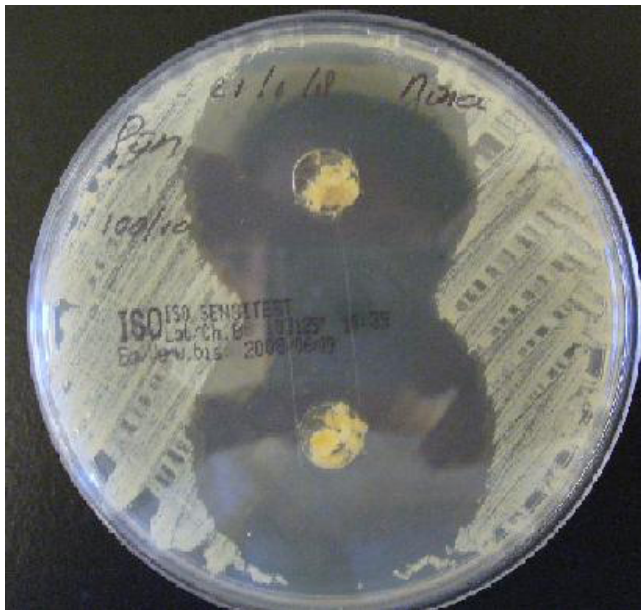Five different antibiotic solutions – cefazolin 6.0 mg/ml, clindamycin 2.5 mg/ml, linezolid 3.0 mg/ml, oxacillin 0.1 mg/ml and vancomycin 7.0 mg/ml – were stored at five different temperatures. For each antibiotic solutions, 9 tubes of 1 ml, were stored at each temperature. After 1 month, 6 months and 1 year of storage, three tubes of each antibiotic solution were brought to room temperature and 0.10  $\mu\text{g}$  of each antibiotic solution was dripped onto a antimicrobial susceptibility test disk which was then placed on an agar.

### Storage of bone chips impregnated with antibiotic solutions

60 tubes, each containing 0.10 g of bone chips from a human morselized femoral head, were impregnated with 60 µg/10 µl cefazolin solution for ten minutes, then 30 were stored at -80°C and 30 at -20°C. Similarly, 60 tubes with 0.10 g bone chips each were impregnated with 70 µg/10 µl vancomycin and 30 were stored at -80°C and 30 at -20°C. Other storage temperatures were not tested, since bone allografts cannot be used for transplantation after storage at temperatures above -20°C for more than one month. After 1 month and 6 months of storage, 20 tubes each of the cefazolin- and the vancomycin-impregnated bone chips (ten tubes from -80°C and 10 tubes from -20°C storage) were thawed and placed on iso agars (Figure 5.1).

### Correlation of antibiotic concentration and zone of inhibition of bone impregnated with vancomycin and cefazolin

Five different cefazolin solutions and five different vancomycin solutions were used to impregnate bone chips from a morselized femoral head and to determine the correlation of antibiotic concentration and zone of inhibition. The concentrations were chosen so as to



**Figure 5.1** Bone chips on an inoculated iso agar.

exceed the minimal inhibitory concentration, and similar to that of the control pills from the clinical routine lab (cefazolin 60µg and vancomycin 70µg). Cefazolin: 0.5 µg/10 µl, 2.5 µg/10 µl, 10 µg/10 µl, 60 µg/10 µl and 100 µg/10 µl; vancomycin: 0.5 µg/10 µl, 2.5 µg/10 µl, 10 µg/10 µl, 70 µg/10 µl and 100 µg/10 µl. For each concentration, ten 0.10 g bone chips were impregnated at room temperature for ten minutes and placed on agar as described above; the mean diameter of the free zone was measured, and the antibiotic quantity was correlated to the zone of inhibition.

### **Determination of the maximum amount of antibiotics absorbed by bone chips**

One gram of bone chips from a morselized femoral head was impregnated with 5 ml of cefazolin or vancomycin solution. The maximum absorbed amount was then calculated based on the correlation between antibiotic concentration and zone of inhibition determined earlier.

Chips were impregnated with four different cefazolin solutions (1000 µg/5 ml, 750 µg/5 ml, 500 µg/5 ml and 250 µg/5 ml) and with four different vancomycin solutions (5000 µg/5 ml, 2500 µg/5 ml, 1000 µg/5 ml and 250 µg/5 ml). After ten minutes of impregnation the remaining solution was poured off. 0.10 gram was taken off the impregnated 1 gram and placed on an inoculated agar; this was repeated five times. The zone of inhibition around the chips was measured. Matching this zone to a zone of inhibition in the correlation analysis performed earlier yielded the matching amount of antibiotics and thus the maximum amount of antibiotic that can be absorbed at this concentration. In a repeat test, after the antibiotic solution was poured off the bone chips were rinsed twice with 5.0 ml saline in order to remove any antibiotic solution remaining on the surface of the bone chips; thus, the real amount absorbed by the bone chips was calculated.

## **RESULTS**

### **Storage of antibiotics**

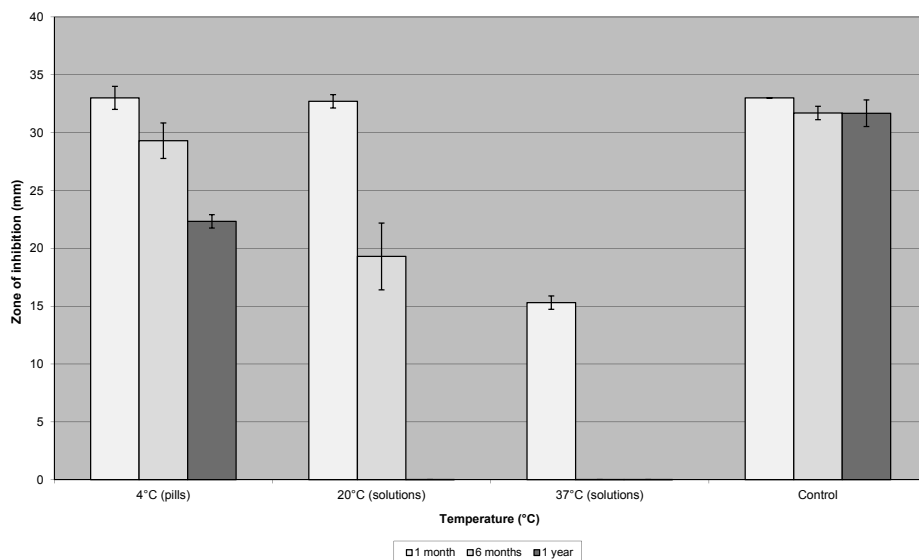
No differences were seen, compared to controls, in the zone of inhibition for cefazolin, vancomycin, linezolid and clindamycin pills that had been stored at -80°C, -20°C, 4°C, 20°C and 37°C for 1 month, 6 months and 1 year. Also, no differences in response at any

of these temperatures were found for clindamycin and linezolid solutions that had been stored for 12 months.

Oxacillin pills stored at 4°C for 12 months showed a decreased zone of inhibition compared to controls. Oxacillin solutions showed a decreased zones of inhibition after 1 month of storage at 37°C and after 6 months of storage at 20°C. No zone of inhibition could be found after 12 months of storage at 20°C and after 6 months of storage at 37°C (Figure 5.2). At other temperatures, no differences in the zone of inhibition were seen compared to controls.

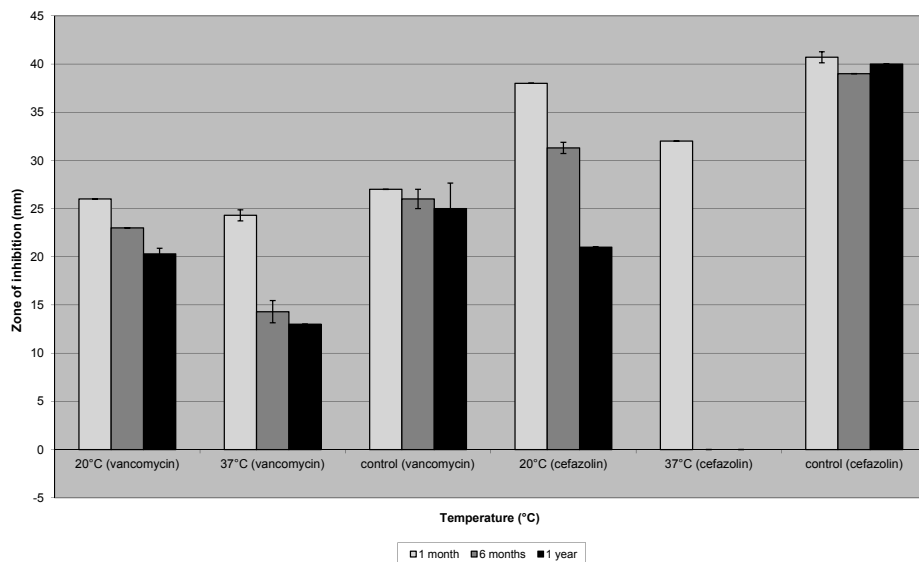
Vancomycin solutions stored at 37°C for 6 months showed a decreased zone of inhibition, while the zone of inhibition was not affected after 1 month of storage at this temperature (Figure 5.3). At -80°C, -20°C and 4°C no differences were visible compared to controls as was the case for vancomycin solutions stored at 20°C for 6 months; however, 12 months at 20°C did result in a decreased zone of inhibition (Figure 5.3).

For cefazolin solutions, the zone of inhibition was decreased when compared to controls after storage at 37°C for 1 month and at 20°C for 6 and 12 months. No zone of inhibition could be seen after 6 and 12 months of storage at 37°C (Figure 5.3).



**Figure 5.2** Storage of oxacillin pills (1 µg) at 4°C or oxacillin solutions (0.1 mg/ml) at 20°C and 37°C for 1 month, 6 months and 12 months compared to controls.





**Figure 5.3** Storage of cefazolin solutions (6.0 mg/ml) or vancomycin solutions (7.0 mg/ml) at 20°C and 37°C for 1 month, 6 months and 12 months compared to controls.

### Storage of bone chips impregnated with antibiotics

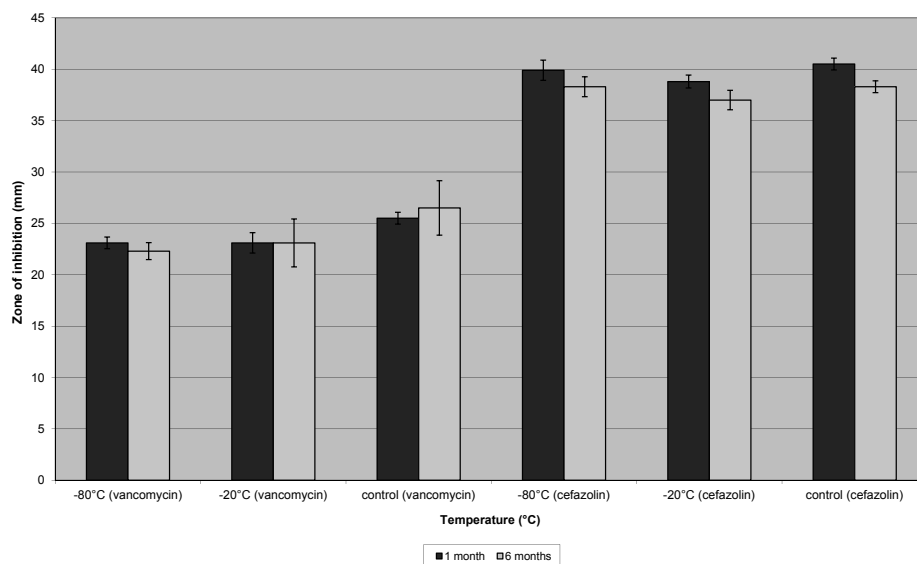
Bone chips impregnated with vancomycin or cefazolin, stored at -20°C and -80°C for 6 months did not show a difference in zone of inhibition when compared to controls (Figure 5.4).

### Correlation of antibiotic concentration and zone of inhibition of bone chips impregnated with vancomycin and cefazolin

The correlation of antibiotic quantity and zone of inhibition of bone chips impregnated with cefazolin and vancomycin is presented in Figure 5.5. A curve was fitted between the quantity of antibiotic and diameter of inhibition zone measured. With increasing antibiotic quantity, the zone of inhibition increases logarithmically.

### Determination of the maximum absorbed amount

Table 5.1 represents the results of the impregnating bone chips with 5 ml cefazolin or vancomycin solution. The zones of inhibition of 0.10 g bone chips impregnated with 5

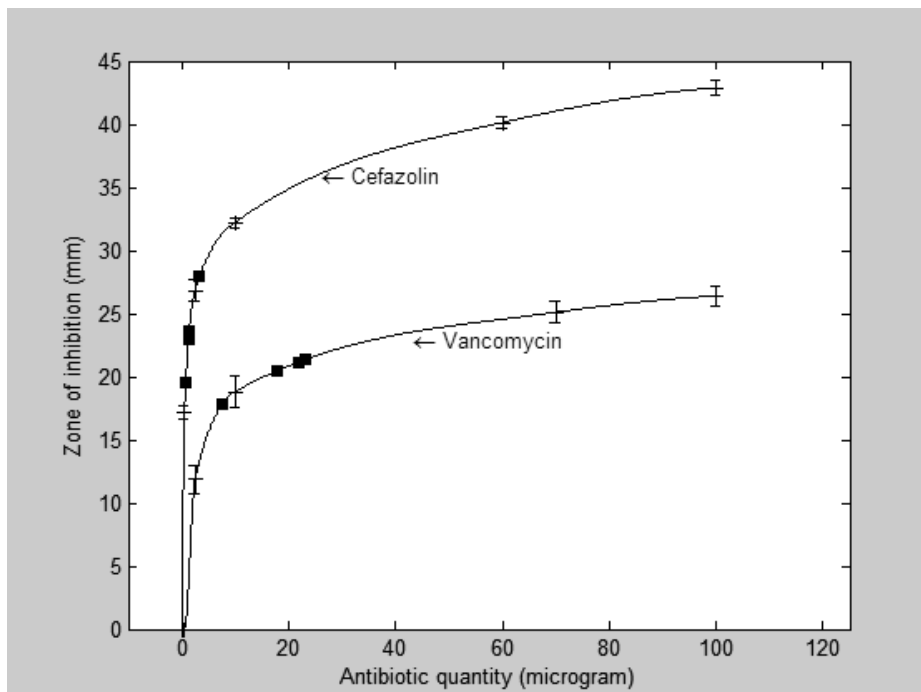


**Figure 5.4** Storage of bone chips impregnated with cefazolin solution (6.0 mg/ml) or vancomycin solution (7.0 mg/ml) at -80°C and -20°C for 1 month and 6 months compared to controls.

**Table 5.1** Impregnation of bone chips with cefazolin and vancomycin solutions

Antibiotic	Rinsing with 0.9% saline, +/-	Antibiotic content of impregnation fluid ( $\mu\text{g}/5\text{ ml}$ )	Mean diameter of <i>S. epidermidis</i> -free zone (mm)	Mean antibiotic content of 1.0 g of bone chips ( $\mu\text{g}$ )
Cefazolin	+	1000	$28.0 \pm 1.2$	32
	+	750	$23.6 \pm 1.3$	15
	+	500	$23.0 \pm 1.2$	13
	+	250	$19.6 \pm 0.5$	7
	-	1000	$32.4 \pm 0.9$	105
	-	750	$31.8 \pm 0.8$	92
	-	500	$29.0 \pm 2.4$	44
	-	250	$28.6 \pm 0.5$	39
Vancomycin	+	5000	$23.2 \pm 0.5$	214
	+	2500	$22.0 \pm 1.0$	212
	+	1000	$17.8 \pm 1.1$	204
	+	250	$7.6 \pm 6.9$	178
	-	5000	$24.2 \pm 0.8$	215
	-	2500	$23.6 \pm 1.1$	214
	-	1000	$22.8 \pm 3.3$	212
	-	250	$16.0 \pm 0.7$	201

Antibiotic quantity of 1.0 g bone chips, with and without rinsing of the bone chips, is calculated using the regression analysis of the antibiotic solution (Figure 5.5).



**Figure 5.5** Regression analysis of bone chips impregnated with antibiotic solutions. Squares represent the inhibition zones for 0.10 g of bone chips taken from 1.0 g of bone chips impregnated with 5 ml of antibiotic solution and rinsed with saline twice; the fitted curves yield the corresponding antibiotic content.

ml antibiotic solution (and rinsed with saline twice) are related to antibiotic quantity in Figure 5.5 (represented by the squares). The associated quantity of antibiotic present in 0.10 g of chips can then be read from the figure, and from this, the antibiotic content of 1.0 g bone chips is determined (Table 5.1).

## DISCUSSION

### Storage of antibiotics

The effects of different storage temperatures on antibiotics were studied. In addition, we examined the reaction to freezing of bone chips impregnated with antibiotics. It can be concluded that storage at  $-80^{\circ}\text{C}$  and  $-20^{\circ}\text{C}$  does not affect the activity of antibiotics for 1

year, and that, of bone chips impregnated with cefazolin and vancomycin up to 6 months. This shows that bone chips can be impregnated with antibiotics before storage in a bone bank. This makes surgery easier, safer and less time-consuming for the orthopaedic surgeon since they do not have to add the antibiotics during the procedure and faults can be avoided this way.

### **Correlation of antibiotic quantity and zone of inhibition of bone impregnated with vancomycin and cefazolin and determination of the maximum absorbed amount**

Numerous studies have concluded that morselized bone can act as a carrier for antibiotics [19-25]. These studies show that prophylactic use of bone chips impregnated with antibiotics can be effective. However, the amount of antibiotics present in the bone chips after impregnation was not determined in any of these studies, while antibiotics are effective only if their concentration is high enough to eradicate bacteria. Our study investigated the reactions, *in vitro*, of *S. epidermidis* to bone chips impregnated with cefazolin and vancomycin solutions. Correlation of antibiotic quantity and zone of inhibition of bone chips impregnated with the antibiotic solutions show that increasing amounts of cefazolin and vancomycin increase the zone of *S. epidermidis* inhibition logarithmically. At therapeutic concentrations, the correlation analysis is a good reproduction of reality, even though the zones of inhibition at high concentrations are probably not very reliable. The question can be asked whether it is necessary to use the maximum local amounts of antibiotics obtainable. It is apparent from figure 5 that increasing the antibiotic amount to above approximately 20 µg per 0.1 gram bone chips will not significantly increase the zone of inhibition. This suggests that approximately 20 µg per 0.1 gram bone chips is sufficient to eradicate the bacteria *in vitro*.

Local antibiotic therapy has to meet several other requirements in addition to that of sufficient concentration at the site of infection. Drug delivery has to be controlled in order to ensure that known adverse drug effects like deafness or renal failure are prevented [22]. Also, antibiotic concentrations should not be cytotoxic to osteoblasts or bone tissue. According to Edin, Miclau et al. [27], local levels of vancomycin of <1000 µg/ml do not affect osteoblast replication. Cefazolin at concentrations of 200 µg/ml decreases cell replication, but does not affect the replication of osteoblasts at levels of 100 µg/ml. The concentrations of cefazolin and vancomycin solutions in our study were neither toxic to osteoblasts nor able to cause systemic side effects, but were very effective against

*S. epidermidis in vitro*. However, the concentrations needed in prophylaxis against infections might be different.

To our knowledge, no studies have investigated how long high local antibiotic concentrations must be sustained to obtain effective infection prophylaxis. The prolonged release of antibiotics from antibiotic-containing bone cement did not protect against late hematogenous infections [28]. For prevention, a high local antibiotic concentration will be effective, even if this is only for a short time; one or two days, or even a few hours, can be sufficient. As long as the concentration of vancomycin and cefazolin is above the minimal inhibitory concentration (MIC) for *S. epidermidis*, it will have the maximum effect. The concentrations used in this study are well above MIC; taking into account the half-life of these antibiotics, they will stay above MIC – and be effective – for at least 8 to 10 hours. For therapeutic use, the carrier may be more effective if the antibiotic concentration is high for a longer period, preferably for 2–4 weeks. The diffusion of the antibiotic into the infected tissues takes time, as does the killing process of the bacteria.

Witso et al. [22] have shown that the elution profile from bone chips is different for different antibiotics. The elution profile of cephalosporins (cefazolin) shows a high initial release with rapid decay. After three days, all the antibiotics are eluted from the bone chips, leaving no subinhibitory amount of drug that could induce resistance. Therefore, cefazolin is a good choice for local prophylaxis. However, cephalosporins carry a small risk of hypersensitivity[29]. Vancomycin is another good choice for impregnating bone chips; it has low resistance and allergy rate and, like cefazolin, is very effective against *S. epidermidis* and *Staphylococcus aureus*, the main pathogens colonizing biomaterials [26]. The elution profile of vancomycin is not as steep as that of cefazolin, with some elution even after seven days.

From past experience, it is likely that it will only be a matter of time before bacteria develop a mechanism of resistance against any new locally applied antibiotic. Therefore, further research into the use of combinations of antibiotics, i.e. multidrug targeting, is in order [30].

Differences between rinsing with saline and not rinsing the bone chips after impregnation were also studied. We hypothesized that rinsing the bone chips would remove antibiotic solution remaining on the surface of the chips. With cefazolin, bone chips rinsed with saline twice had a smaller free zone than bone chips that were not rinsed. This difference was not found with vancomycin. The activity of the antibiotics against *S. epidermidis*

was still evident after rinsing the bone chips with saline, and high enough to eradicate the bacteria. It can therefore be concluded that the antibiotics are absorbed by the bone chips and the activity does not stem from antibiotic solution remaining on the surface of the bone chips. *In vivo* research is needed to assess the clinical value of antibiotics-impregnated bone chips.

## Conclusions

In conclusion, storage at  $-80^{\circ}\text{C}$  and  $-20^{\circ}\text{C}$  of antibiotic solutions, antibiotic pills and bone chips impregnated with cefazolin and vancomycin does not affect the activity of the drugs for at least one year. It is therefore possible to impregnate bone chips with antibiotics and store them in a bone bank at one of these temperatures. Also, storage of antibiotic pills at temperatures up to  $37^{\circ}\text{C}$  for 12 months does not affect their activity. However, storage of antibiotic solutions at temperatures above  $20^{\circ}\text{C}$  does affect the activity of some of the antibiotics investigated.

Based on the correlation of antibiotic quantity and zone of inhibition for cefazolin and vancomycin, optimal concentration(s) for impregnation of bone chips were determined. The correlation provides the opportunity to determine the antibiotic content of the bone chips so that a safe and reproducible bone bank product can be developed.

## REFERENCES

1. Whitehouse JD, Friedman ND, Kirkland KB, Richardson WJ, Sexton DJ: **The impact of surgical-site infections following orthopedic surgery at a community hospital and a university hospital: adverse quality of life, excess length of stay, and extra cost.** *Infect Control Hosp Epidemiol* 2002, **23**(4):183-189.
2. Plowman R: **The socioeconomic burden of hospital acquired infection.** *Euro Surveill* 2000, **5**(4):49-50.
3. Slooff TJ, Huiskes R, van Horn J, Lemmens AJ: **Bone grafting in total hip replacement for acetabular protrusion.** *Acta Orthop Scand* 1984, **55**(6):593-596.
4. Gie GA, Linder L, Ling RS, Simon JP, Slooff TJ, Timperley AJ: **Impacted cancellous allografts and cement for revision total hip arthroplasty.** *J Bone Joint Surg Br* 1993, **75**(1):14-21.
5. Schreurs BW, Bolder SB, Gardeniers JW, Verdonschot N, Slooff TJ, Veth RP: **Acetabular revision with impacted morsellised cancellous bone grafting and a cemented cup. A 15- to 20-year follow-up.** *J Bone Joint Surg Br* 2004, **86**(4):492-497.

6. Schreurs BW, Thien TM, de Waal Malefijt MC, Buma P, Veth RP, Slooff TJ: **Acetabular revision with impacted morselized cancellous bone graft and a cemented cup in patients with rheumatoid arthritis: three to fourteen-year follow-up.** *J Bone Joint Surg Am* 2003, **85-A(4)**:647-652.
7. Schreurs BW, Luttjeboer J, Thien TM, de Waal Malefijt MC, Buma P, Veth RP, Slooff TJ: **Acetabular revision with impacted morselized cancellous bone graft and a cemented cup in patients with rheumatoid arthritis. A concise follow-up, at eight to nineteen years, of a previous report.** *J Bone Joint Surg Am* 2009, **91(3)**:646-651.
8. Schreurs BW, Slooff TJ, Gardeniers JW, Buma P: **Acetabular reconstruction with bone impaction grafting and a cemented cup: 20 years' experience.** *Clin Orthop Relat Res* 2001(393):202-215.
9. Schreurs BW, Arts JJ, Verdonschot N, Buma P, Slooff TJ, Gardeniers JW: **Femoral component revision with use of impaction bone-grafting and a cemented polished stem.** *J Bone Joint Surg Am* 2005, **87(11)**:2499-2507.
10. Schreurs BW, Arts JJ, Verdonschot N, Buma P, Slooff TJ, Gardeniers JW: **Femoral component revision with use of impaction bone-grafting and a cemented polished stem. Surgical technique.** *J Bone Joint Surg Am* 2006, **88 Suppl 1 Pt 2**:259-274.
11. Schreurs BW, Slooff TJ, Buma P, Gardeniers JW, Huiskes R: **Acetabular reconstruction with impacted morsellised cancellous bone graft and cement. A 10- to 15-year follow-up of 60 revision arthroplasties.** *J Bone Joint Surg Br* 1998, **80(3)**:391-395.
12. Parvizi J, Saleh KJ, Ragland PS, Pour AE, Mont MA: **Efficacy of antibiotic-impregnated cement in total hip replacement.** *Acta Orthop* 2008, **79(3)**:335-341.
13. Parvizi J, Pour AE, Keshavarzi NR, D'Apuzzo M, Sharkey PF, Hozack WJ: **Revision total hip arthroplasty in octogenarians. A case-control study.** *J Bone Joint Surg Am* 2007, **89(12)**:2612-2618.
14. Blom AW, Taylor AH, Pattison G, Whitehouse S, Bannister GC: **Infection after total hip arthroplasty. The Avon experience.** *J Bone Joint Surg Br* 2003, **85(7)**:956-959.
15. Isefuku S, Joyner CJ, Simpson AH: **Gentamicin may have an adverse effect on osteogenesis.** *J Orthop Trauma* 2003, **17(3)**:212-216.
16. Gristina AG, Costerton JW: **Bacterial adherence to biomaterials and tissue. The significance of its role in clinical sepsis.** *J Bone Joint Surg Am* 1985, **67(2)**:264-273.
17. van de Belt H, Neut D, Schenk W, van Horn JR, van der Mei HC, Busscher HJ: **Infection of orthopedic implants and the use of antibiotic-loaded bone cements. A review.** *Acta Orthop Scand* 2001, **72(6)**:557-571.
18. Winkler H, Kaudela K, Stoiber A, Menschik F: **Bone grafts impregnated with antibiotics as a tool for treating infected implants in orthopedic surgery - one stage revision results.** *Cell Tissue Bank* 2006, **7(4)**:319-323.
19. Witso E, Persen L, Benum P, Bergh K: **Release of netilmicin and vancomycin from cancellous bone.** *Acta Orthop Scand* 2002, **73(2)**:199-205.
20. Witso E, Persen L, Benum P, Aamodt A, Husby OS, Bergh K: **High local concentrations without systemic adverse effects after impaction of netilmicin-impregnated bone.** *Acta Orthop Scand* 2004, **75(3)**:339-346.

21. Winkler H, Janata O, Berger C, Wein W, Georgopoulos A: **In vitro release of vancomycin and tobramycin from impregnated human and bovine bone grafts.** *J Antimicrob Chemother* 2000, **46**(3):423-428.
22. Witso E, Persen L, Loseth K, Benum P, Bergh K: **Cancellous bone as an antibiotic carrier.** *Acta Orthop Scand* 2000, **71**(1):80-84.
23. Witso E, Persen L, Benum P, Bergh K: **Cortical allograft as a vehicle for antibiotic delivery.** *Acta Orthop* 2005, **76**(4):481-486.
24. Buttaro MA, Gimenez MI, Greco G, Barcan L, Piccaluga F: **High active local levels of vancomycin without nephrotoxicity released from impacted bone allografts in 20 revision hip arthroplasties.** *Acta Orthop* 2005, **76**(3):336-340.
25. Buttaro MA, Gonzalez Della Valle AM, Pineiro L, Mocetti E, Morandi AA, Piccaluga F: **Incorporation of vancomycin-supplemented bone incorporation of vancomycin-supplemented bone allografts: radiographical, histopathological and immunohistochemical study in pigs.** *Acta Orthop Scand* 2003, **74**(5):505-513.
26. Montanaro L, Arciola CR, Baldassarri L, Borsetti E: **Presence and expression of collagen adhesin gene (cna) and slime production in Staphylococcus aureus strains from orthopaedic prosthesis infections.** *Biomaterials* 1999, **20**(20):1945-1949.
27. Edin ML, Miclau T, Lester GE, Lindsey RW, Dahners LE: **Effect of cefazolin and vancomycin on osteoblasts in vitro.** *Clin Orthop Relat Res* 1996(333):245-251.
28. Malizos NK, Roidis NT, Karachalios TS, Poultsides LA, Bargiotas KA: **Management of Septic Joint Arthroplasty - The Hellenic Experience.** In: *Local Antibiotics in Arthroplasty State of the art from an interdisciplinary point of view.* Edited by Walenkamp GHIM. New York: Georg Thieme Verlag; 2007: 109-119.
29. Wininger DA, Fass RJ: **Antibiotic-impregnated cement and beads for orthopedic infections.** *Antimicrob Agents Chemother* 1996, **40**(12):2675-2679.
30. Murray PR, Rosenthal KS, Kobayashi GS, Pfaller MA: **Medical Microbiology**, 3 edn. St. Louis: Mosby; 1998.



## CHAPTER 6

# THE EFFECT OF DOOR-OPENINGS ON NUMBERS OF COLONY FORMING UNITS IN THE OPERATING ROOM IN HIP REVISION SURGERY

Nina M.C. Mathijssen, Gerjon Hannink, Patrick D.J. Sturm, Peter Pilot, Rolf M. Bloem,  
Pieter Buma, Pieter L.C. Petit, B. Willem Scheurs

Submitted

## ABSTRACT

**Background:** Intraoperative bacterial contamination has been related to the occurrence of periprosthetic infection.

**Aim:** It was hypothesized that a reduced frequency of door-openings leads to a reduced number of CFUs during surgery.

**Methods:** During 70 hip revision surgeries operation circumstances were monitored by measuring numbers of particles and CFUs. The number of door-openings, the number of people and the duration of the surgery were registered; the number of particles and number of CFUs/m<sup>3</sup> were measured. Logistic regression analysis was used to determine the relation between the different parameters measured during surgery and the number of CFUs/m<sup>3</sup>. Medical files of all patients were reviewed to assess the occurrence of an infection post-operatively.

**Findings:** An average number of 78 ( $\pm 83$ ) CFUs/m<sup>3</sup> was measured. An average number of 4.5 ( $\pm 4.8$ ) door-openings/hour was found. Mean operation time was 151 ( $\pm 47$ ) minutes and the average number of people present during the surgery was 8 ( $\pm 1.5$ ). No significant relation was found between the number of door-openings and the number of CFUs/m<sup>3</sup> during surgery ( $p=0.08$ ; OR 0.14 (0.02–1.24)). Other parameters were not associated with the number of CFUs/m<sup>3</sup> during the hip revision surgeries. Mean follow-up of all patients was 28 months ( $\pm 14.6$ ). One patient developed an infection postoperatively (1.4%).

**Conclusion:** In conclusion, no significant relation was found between the number of door-openings and the variation of CFUs/m<sup>3</sup>. Moreover, the number of people present during surgery and the time of the surgery were not related to the variation of CFUs/m<sup>3</sup>.

## INTRODUCTION

Total hip arthroplasties (THAs) are very successful and frequently performed surgeries [1]. Despite the success of these surgeries, infection occurs in approximately 0.5 to 3% of all primary THAs and in 4 to 6% of all revision THAs [1, 2]. Infection is a potentially devastating complication; patients may require further surgery, additional nursing care and prolonged hospital stay. Moreover, it might result in a reduced quality of life and more physical limitations [3, 4]. Furthermore, the costs of hospitalisation of an infected patient are about 3 to 4 times higher than those of an uninfected patient [4]. Intraoperative bacterial contamination has been related to the occurrence of periprosthetic infection [5]. Intraoperative contamination of the wound may occur with the patient's skin flora or with the commensal flora of the theatre personnel through instruments and other materials [6]. In addition, studies have shown that most airborne bacteria reach the wound area via the hands of the surgical personnel or by the instruments used [7, 8].

Several studies have investigated the presence of airborne bacteria in the operating theatre, factors that influence their numbers, and their role in intraoperative infection, all with different conclusions [5, 9-13]. To minimize periprosthetic infection, it was proposed by the Hospital Infection Society Working Party on Infection Control in Operating Theatres (HISWPICOT) that during high-risk operations, such as orthopaedic implant surgery, the number of colony forming units (CFUs) in air should not exceed 10 CFU/m<sup>3</sup> at 30 cm distance from the wound and not exceed 20 CFUs/m<sup>3</sup> directly around this zone [14]. In non high-risk surgery, a maximum of 180 CFUs/m<sup>3</sup> is allowed. The advice of the HISWPICOT is also adopted in The Netherlands, however strict rules on maximum CFUs or rules on discipline in the operating theatre are not available.

In this study the air quality in the operating theatre during hip revision surgery and the influence of door-openings on air quality were investigated by measuring the number of CFUs/m<sup>3</sup>. It was hypothesized that minimizing the number of door-openings would lead to reduced numbers of CFUs during surgery.

## MATERIALS AND METHODS

### Setting

This observational study evaluated air quality in the operating room during revision hip arthroplasties and was embedded in another study on bone grafts [15]. Hence, consecutive revision hip surgeries with bone impaction grafting (BIG) were included. Between February 2009 and December 2011, 70 hip revision surgeries with BIG were included.

The study was performed at the Departments of Orthopaedics at the Radboud University Nijmegen Medical Center in Nijmegen, and the Reinier de Graaf Hospital in Delft, the Netherlands. In Nijmegen, 59 surgeries were monitored, the remaining 11 surgeries in Delft. The study was approved by the local Medical Ethics Committees and written informed consent was obtained from all patients.

Both operating theatres have turbulent-flow ventilation systems equipped with HEPA filters, which are 99.97% efficient in removing airborne particles of 0.3  $\mu\text{m}$  or larger. In Nijmegen, the HEPA filters are replaced every 6 months and maintenance work on the system is carried out periodically. The operating room is under positive pressure in relation to the adjacent rooms (5 Pa), air temperature and humidity are set respectively at 18°C and 56–60%. In Delft, the HEPA filters are replaced every 12 months. The operating room is under positive pressure in relation to the adjacent rooms (15 Pa), air temperature is set at 18°C and humidity at 50–65%. In Delft, exhaust body suits were used by the operating team.

Factors that may influence the air quality were registered, including the number of door-openings, the number of sterile and non-sterile people, and the duration of the surgery.

### Air quality measurements

The number of particles in the air was measured with an Airborne Particle Counter (APC Plus, Kregliner Europe, Antwerp, Belgium), every 10 minutes for 1 minute during the surgery at a distance of approximately 1.5 meter of the wound. The APC Plus counter was positioned horizontally at wound height and directed towards the wound. Particles were detected in four diameter thresholds:  $>0.3 \mu\text{m}$ ,  $>0.5 \mu\text{m}$ ,  $>1.0 \mu\text{m}$ , and  $>5.0 \mu\text{m}$ . The number of CFUs/ $\text{m}^3$  was measured 4 times during surgery: directly after incision, directly after opening of the container of the allograft bone, at the time this bone graft was first used in the procedure, and again 10 minutes later.

At the same position as the Airborne Particle Counter, 200 l of air with an airflow rate of 100 l/min was aspirated with the High Flow Microbial Airborne Sampler (RCS High Flow, Kregliner Europe, Antwerp, Belgium) containing an RCS-strip with Tryptic Soy Agar (TSA, Kregliner Europe, Antwerp, Belgium). A sedimentation plate (TSA, Kregliner Europe, Antwerp, Belgium) was placed on the instrument table for 1 hour from the moment of opening the container of the allograft bone. The numbers of CFUs on the RCS-strips as well as on the sedimentation plate were counted manually after 48 h of incubation at 30 °C. The number of CFUs on the RCS-strips and the sedimentation plates were converted to number of CFUs/m<sup>2</sup>/hour and number of CFUs/m<sup>3</sup>, respectively.

### Follow-up

The medical files of all patients were reviewed, including clinical, radiological, and laboratory findings, to assess the occurrence of an infection post-operatively.

### Data analysis

Outliers in CFUs/m<sup>3</sup> were defined as values higher as the 95<sup>th</sup> percentile and subsequently replaced by the 95<sup>th</sup> percentile value. To discriminate between numbers of CFUs/m<sup>3</sup> at the four different time points during the hip revision surgery, a Friedman test was used. Since no differences between the four different time points could be measured, mean CFUs/m<sup>3</sup> for each operation was calculated.

Logistic regression analysis was performed to determine the relation between the different variables measured during surgery and the number of CFUs/m<sup>3</sup>. According to the proposal of the HISWPICOT, 20 CFUs/m<sup>3</sup> is the maximum acceptable number of CFUs during high-risk operations. Therefore, the variable CFUs/m<sup>3</sup> was dichotomized in either 'acceptable' ( $\leq 20$  CFUs/m<sup>3</sup>) or 'not acceptable' ( $> 20$  CFUs/m<sup>3</sup>). First, univariate logistic regression analyses were performed for the number of door-openings, operation time, number of people present during surgery (total number as well as the number of people non-sterile), hospital, the number of particles measured during surgery and the number of CFUs/m<sup>2</sup>/hour measured with the sedimentation plate. A normal distribution could not be assumed for the number of particles, the number of door-openings, the number of people present during surgery (total number as well as the number of people non-sterile) and the number of CFUs/m<sup>2</sup>/hour measured with the sedimentation plate. The number of particles were log transformed to obtain values with a normal distribution. The other variables for which a

normal distribution could not be assumed were dichotomized into 'low' (lower or equal to the mean) and 'high' (higher than the mean). Variables that were associated with the outcome in univariate analyses ( $p < 0.20$ ) were included in multivariate logistic regression analyses.

All statistical analyses were performed using IBM SPSS statistics 20.0 (Chicago, Illinois). P-values  $< 0.05$  were considered statistically significant.

## RESULTS

### Air quality during hip revision arthroplasties

One surgical procedure was excluded because the patient was intra-operatively resuscitated, resulting in severe violation of all sterility protocols. Therefore, 69 hip revision surgeries were analysed

The results of the 69 hip revision arthroplasties are summarized in Table 6.1. An average number of 4.5 ( $\pm 4.8$ ) door-openings/hour was found. Mean operation time was 151 ( $\pm 47$ ) minutes and the average number of people present during the surgery was 8 ( $\pm 1.5$ ). The mean number of CFU/m<sup>3</sup> was 78 ( $\pm 83$ ), no differences could be found between numbers of CFUs/m<sup>3</sup> at the four different time points during surgery ( $p = 0.2$ ). During 14 surgeries an acceptable number (according to HISWPICOT) of less than 20 CFUs/m<sup>3</sup> was measured and during 55 surgeries this number was exceeded.

Univariate logistic regression showed that the number of door-openings and mean number of particles of  $> 0.3 \mu\text{m}$ ,  $> 0.5 \mu\text{m}$  and  $> 1.0 \mu\text{m}$  had p-values  $< 0.20$  (Table 6.1). These variables were included in multivariate logistic regression. Operation time, number of people present during surgery and CFU/m<sup>2</sup>/hour measured with the sedimentation plate were not associated with the number of CFUs/m<sup>3</sup> during the surgery. The variable 'hospital' (Nijmegen vs. Delft) was excluded from the analyses because one of the cells in the contingency table was zero. In other words, there were not enough observations to draw any conclusions for this variable.

Because of multicollinearity between mean number of particles of  $> 0.3 \mu\text{m}$ ,  $> 0.5 \mu\text{m}$  and  $> 1.0 \mu\text{m}$ , only the results of  $> 0.5 \mu\text{m}$  were used for multivariate analysis since they were most significant after univariate analysis (Table 6.1). Multivariate analysis showed that there was no significant relation between number of door-openings and the number of CFUs/m<sup>3</sup> during surgery ( $p = 0.08$ ). Moreover, the mean number of particles  $> 0.5 \mu\text{m}$  was

**Table 6.1** Overview of variables measured during 69 revision hip arthroplasties and results of univariate and multivariate logistic regression analyses

Variable	Mean ( $\pm$ SD)	Univariate LR odds ratio (95% CI)	p-value	Multivariate LR odds ratio (95% CI)	p-value
Number of door-openings/hour <sup>1</sup>	4.5 $\pm$ 4.8	0.12 (0.014–0.95)	0.04	0.14 (0.02–1.24)	0.08
Number of people present during surgery <sup>1</sup>	7.8 $\pm$ 1.5	0.82 (0.23–2.98)	0.77		
Particles >0.3 $\mu\text{m}^\#$	5464 $\pm$ 6674	1.62 (0.87–3.0)	0.13		
Particles >0.5 $\mu\text{m}^\#$	547 $\pm$ 756	1.96 (0.99–3.93)	0.06	1.67 (0.82–3.43)	0.16
Particles >1.0 $\mu\text{m}^\#$	67 $\pm$ 74	1.79 (0.77–4.18)	0.18		
Particles >5.0 $\mu\text{m}^\#$	4.2 $\pm$ 2.5	0.55 (0.19–1.57)	0.26		
CFU/m <sup>2</sup> /hour <sup>1</sup>	2276 $\pm$ 4196	0.54 (0.16–1.84)	0.32		
Operation time (min)	151 $\pm$ 47	0.99 (0.98–1.01)	0.32		
Number of people non-sterile <sup>1</sup>	4.4 $\pm$ 1.3	1.07 (0.29–3.92)	0.92		

<sup>#</sup> Number of particles was log transformed. <sup>1</sup> Variables were dichotomised into 'low' (lower than the mean) and 'high' (higher or equal to the mean). LR=logistic regression.

not associated with the number of CFUs/m<sup>3</sup> during the hip revision surgeries ( $p=0.16$ ). Odds ratios were 0.14 (0.02–1.24) and 1.67 (0.82–3.43) for door-openings/hour and mean number of particles of >0.5  $\mu\text{m}$ , respectively.

## Follow-up

Mean follow-up (FU) of all patients was 28 months ( $\pm 14.6$ ). Mean age at operation was 67.4 ( $\pm 10.9$ ) years. Of the patients, 56% was female.

One patient developed an infection postoperatively (1.4%). This infection was caused by coagulase negative Staphylococcus (CoNS) and Enterobacteriae. Number of CFUs/m<sup>3</sup> during the surgery was 11.3 and numbers of door-openings/hour was 1.6 in this case.

## DISCUSSION

In this study we measured the numbers of CFUs during 69 hip revision arthroplasties in combination with BIG. It was hypothesized that a reduced frequency of door-openings leads to a reduced number of CFUs during surgery.

We did not find a significant association between door-openings and CFUs/m<sup>3</sup> in our study ( $p=0.08$ ). The odds ratio of door-openings/hour after multivariate analysis was 0.14 (0.02–1.24), meaning that if the number of door-openings/hour increases to more than 4.5, the risk of a number of CFUs/m<sup>3</sup> of more than 20 (the HISWPICOT criterion), increases 7 times ( $1/0.14$ ). The number of surgeries included in our study was probably not high enough to detect a significant relation. Moreover, the 95% CI of the odds ratio of door-openings/hour varies greatly, probably because the results of CFUs/m<sup>3</sup> varied throughout the surgeries performed. This variation in CFUs/m<sup>3</sup> between the different surgeries is in accordance with the results of previous reports [13, 16].

Only if strictly necessary, doors were allowed to be opened in both hospitals. This resulted in a very low average number of door-openings/hour ( $4.5\pm 4.8$ ). This average number is very low when compared to other studies [16-21]. This might also explain the absence of a significant association between door-openings and CFU/m<sup>3</sup>. Other studies also reported no significant contribution of door-openings to the number of CFUs/m<sup>3</sup> [13, 22]. However, Andersson et al. [23], found that 34% of the variance in CFUs/m<sup>3</sup> could be explained by door-opening during the surgery, although the number of door-openings per hour in their study was much higher when compared to our study. A relation between increased number of door-openings and the risk of infection has been suggested by several authors [18, 20, 21], however could not be confirmed by the present study.

The HISWPICOT proposed a maximum of 20 CFUs/m<sup>3</sup> at a distance of more than 30 cm of the wound during implant surgery. When this criterion of <20 CFUs/m<sup>3</sup> was taken as reference, 14 out of 69 operations did meet this criterion. Moreover, in all 69 hip revision surgeries performed, only during 2 operations the proposed criterion of <10 CFUs/m<sup>3</sup> (at a distance of 30 cm of the wound) was met. Air quality measurements performed by Andersson et al. [16] and by Stocks et al. [13] during joint arthroplasties also exceeded the recommended level of <10 CFUs/m<sup>3</sup>, although their mean values were lower compared to our results. As is stated by Dharan and Pittet [24], it is not easy to achieve these limits as various factors influence the bio burden during a surgical procedure. In contrast, Ahl et al. [25] did find mean results which not exceeded the proposed limits. They even stated that, when wearing body exhausted clothes, it is possible to achieve numbers <1 CFUs/m<sup>3</sup>.

Ritter [26] suggested to reduce the number of people present during the surgery and to reduce the operating time to decrease the number of bacteria in the air. Moreover, Ong et al. [27] concluded that procedure duration is a significant risk factor for infection. However, we were not able to find a relation between the numbers of CFUs/m<sup>3</sup> and



the operation time or number of people in the operating room. The number of people during the hip revision surgeries in our study was constantly high, since both hospitals were teaching hospitals, which might explain the absence of a relation between number of people and the numbers of CFUs/m<sup>3</sup>. Andersson et al. [16] stated that the duration of the surgery in relation to the total CFU level is of clinical relevance, since the total CFU level increases with increasing duration of surgery, thereby exposing the wound to an increased total number of CFUs and increasing the risk of infection.

No relation between particles, CFUs/m<sup>3</sup> and CFUs/m<sup>2</sup>/hour on the sedimentation plate could be found in this study. Cristina et al. [28] also did not reveal any correlation between particles and numbers of CFUs. They therefore conclude that microbiological monitoring remains the most suitable method for evaluating the air quality in the operating theatre. In contrast, it was stated by Friberg et al. [29] that sedimentation plates are the most realistic indicator of airborne bacterial contamination in the operating room. However, no international consensus on what method to be used for air monitoring is available at this moment, there is still debate on the sampling techniques to be used, their frequency of application and even on the usefulness of such checks and controls [30].

One patient developed an infection in our study. Remarkably, the number of door-openings during this procedure as well as the number of CFUs/m<sup>3</sup> was low.

In conclusion, no significant relation was found between the number of door-openings and the number of CFUs/m<sup>3</sup>. The proposed maximum of <20 CFUs/m<sup>3</sup> during high risk operations by the HISWPICOT was exceeded in this study, although only one patient developed an infection postoperatively. Moreover, the number of people present during surgery and the time of the surgery were not related to the variation of CFUs/m<sup>3</sup>. Particle measurements and the number of CFUs/m<sup>2</sup>/hour measured with the sedimentation plate did not correlate to the numbers of CFUs.

## REFERENCES

1. Pivec R, Johnson AJ, Mears SC, Mont MA: **Hip arthroplasty**. *Lancet* 2012, **380**(9855):1768-1777.
2. Jafari SM, Coyle C, Mortazavi SM, Sharkey PF, Parvizi J: **Revision hip arthroplasty: infection is the most common cause of failure**. *Clin Orthop Relat Res* 2010, **468**(8):2046-2051.
3. Plowman R: **The socioeconomic burden of hospital acquired infection**. *Euro Surveill* 2000, **5**(4):49-50.

4. Whitehouse JD, Friedman ND, Kirkland KB, Richardson WJ, Sexton DJ: **The impact of surgical-site infections following orthopedic surgery at a community hospital and a university hospital: adverse quality of life, excess length of stay, and extra cost.** *Infect Control Hosp Epidemiol* 2002, **23**(4):183-189.
5. Knobben BA, Engelsma Y, Neut D, van der Mei HC, Busscher HJ, van Horn JR: **Intraoperative contamination influences wound discharge and periprosthetic infection.** *Clin Orthop Relat Res* 2006, **452**:236-241.
6. Davis N, Curry A, Gambhir AK, Panigrahi H, Walker CR, Wilkins EG, Worsley MA, Kay PR: **Intraoperative bacterial contamination in operations for joint replacement.** *J Bone Joint Surg Br* 1999, **81**(5):886-889.
7. Whyte W, Hodgson R, Tinkler J: **The importance of airborne bacterial contamination of wounds.** *J Hosp Infect* 1982, **3**(2):123-135.
8. Shaw JA, Bordner MA, Hamory BH: **Efficacy of the Steri-Shield filtered exhaust helmet in limiting bacterial counts in the operating room during total joint arthroplasty.** *J Arthroplasty* 1996, **11**(4):469-473.
9. Verkkala K, Eklund A, Ojarvi J, Tiittanen L, Hoborn J, Makela P: **The conventionally ventilated operating theatre and air contamination control during cardiac surgery-bacteriological and particulate matter control garment options for low level contamination.** *Eur J Cardiothorac Surg* 1998, **14**(2):206-210.
10. Der Tavitian J, Ong SM, Taub NA, Taylor GJ: **Body-exhaust suit versus occlusive clothing. A randomised, prospective trial using air and wound bacterial counts.** *J Bone Joint Surg Br* 2003, **85**(4):490-494.
11. Friberg B, Friberg S, Burman LG: **Inconsistent correlation between aerobic bacterial surface and air counts in operating rooms with ultra clean laminar air flows: proposal of a new bacteriological standard for surface contamination.** *J Hosp Infect* 1999, **42**(4):287-293.
12. Pasquarella C, Pitzurra O, Herren T, Poletti L, Savino A: **Lack of influence of body exhaust gowns on aerobic bacterial surface counts in a mixed-ventilation operating theatre. A study of 62 hip arthroplasties.** *J Hosp Infect* 2003, **54**(1):2-9.
13. Stocks GW, Self SD, Thompson B, Adame XA, O'Connor DP: **Predicting bacterial populations based on airborne particulates: a study performed in nonlaminar flow operating rooms during joint arthroplasty surgery.** *Am J Infect Control* 2010, **38**(3):199-204.
14. Hoffman PN, Williams J, Stacey A, Bennett AM, Ridgway GL, Dobson C, Fraser I, Humphreys H: **Microbiological commissioning and monitoring of operating theatre suites.** *J Hosp Infect* 2002, **52**(1):1-28.
15. Mathijssen NM, Sturm PD, Pilot P, Bloem RM, Buma P, Petit PL, Schreurs BW: **Comparison of contamination of femoral heads and pre-processed bone chips during hip revision arthroplasty.** *Cell Tissue Bank* 2013.
16. Andersson AE, Bergh I, Karlsson J, Eriksson BI, Nilsson K: **Traffic flow in the operating room: An explorative and descriptive study on air quality during orthopedic trauma implant surgery.** *Am J Infect Control* 2012.

17. Lynch RJ, Englesbe MJ, Sturm L, Bitar A, Budhiraj K, Kolla S, Polyachenko Y, Duck MG, Campbell DA, Jr.: **Measurement of foot traffic in the operating room: implications for infection control.** *Am J Med Qual* 2009, **24**(1):45-52.
18. Panahi P, Stroh M, Casper DS, Parvizi J, Austin MS: **Operating room traffic is a major concern during total joint arthroplasty.** *Clin Orthop Relat Res* 2012, **470**(10):2690-2694.
19. Parikh SN, Grice SS, Schnell BM, Salisbury SR: **Operating room traffic: is there any role of monitoring it?** *J Pediatr Orthop* 2010, **30**(6):617-623.
20. Young RS, O'Regan DJ: **Cardiac surgical theatre traffic: time for traffic calming measures?** *Interact Cardiovasc Thorac Surg* 2010, **10**(4):526-529.
21. Pryor F, Messmer PR: **The effect of traffic patterns in the OR on surgical site infections.** *AORN J* 1998, **68**(4):649-660.
22. Ritter MA, Eitzen H, French ML, Hart JB: **The operating room environment as affected by people and the surgical face mask.** *Clin Orthop Relat Res* 1975(111):147-150.
23. Andersson AE, Bergh I, Karlsson J, Eriksson BI, Nilsson K: **Traffic flow in the operating room: an explorative and descriptive study on air quality during orthopedic trauma implant surgery.** *Am J Infect Control* 2012, **40**(8):750-755.
24. Dharan S, Pittet D: **Environmental controls in operating theatres.** *J Hosp Infect* 2002, **51**(2):79-84.
25. Ahl T, Dalen N, Jorbeck H, Hoborn J: **Air contamination during hip and knee arthroplasties. Horizontal laminar flow randomized vs. conventional ventilation.** *Acta Orthop Scand* 1995, **66**(1):17-20.
26. Ritter MA: **Operating room environment.** *Clin Orthop Relat Res* 1999(369):103-109.
27. Ong KL, Kurtz SM, Lau E, Bozic KJ, Berry DJ, Parvizi J: **Prosthetic joint infection risk after total hip arthroplasty in the Medicare population.** *J Arthroplasty* 2009, **24**(6 Suppl):105-109.
28. Cristina ML, Spagnolo AM, Sartini M, Panatto D, Gasparini R, Orlando P, Ottria G, Perdelli F: **Can particulate air sampling predict microbial load in operating theatres for arthroplasty?** *PLoS One* 2012, **7**(12):e52809.
29. Friberg B, Friberg S, Burman LG: **Correlation between surface and air counts of particles carrying aerobic bacteria in operating rooms with turbulent ventilation: an experimental study.** *J Hosp Infect* 1999, **42**(1):61-68.
30. Scaltriti S, Cencetti S, Rovesti S, Marchesi I, Bargellini A, Borella P: **Risk factors for particulate and microbial contamination of air in operating theatres.** *J Hosp Infect* 2007, **66**(4):320-326.



## CHAPTER 7

# DEXA AND HIP REVISION ARTHROPLASTY WITH BONE IMPACTION GRAFTING

Nina M.C. Mathijssen, Sander Mol, Marc A. Hoek, Peter Pilot, Pieter Buma, Rolf M. Bloem  
Submitted

## ABSTRACT

**Background:** Dual-Energy X-ray Absorptiometry (DEXA) for femoral bone impaction grafting and bone remodeling after hip revision surgery was evaluated in this study. Another goal of this study was to see whether DEXA can detect and quantify bony defects in the femur, before hip revision surgery.

**Methods:** This study consisted of two parts; first part was a cadaver study in which 10 femoral specimens from cadaver donors were used to determine bone loss of the femur before hip revision and to evaluate steps of hip revision arthroplasty with bone impaction grafting with DEXA. After each step a DEXA scan was made. The defect created in the femur was weighted and correlated to the bone mineral content and bone mineral density. Second part of this study was an observational pilot study in which bone mineral density (BMD) of the femur of 13 patients, 1 to 5 years after hip revision surgery with bone impaction grafting, was analysed with DEXA.

**Results:** No correlation could be found between the weight of the created defects and the BMD- or BMC-differences in Gruen zone 7 ( $p=0.20$  and  $p=0.28$ , respectively). Moreover, no correlation between the weight of the created defects and the BMD- or BMC-differences in Gruen zone 1 was found ( $p=0.60$  and  $p=0.93$  respectively). Repeatability for all DEXA scans was 1.0 and 0.99 for BMC and BMD respectively. 12 patients were used for evaluation. Mean age was 71.9 ( $\pm 9.5$ ) years. Range of the postoperative scan intervals was 10–63 months after surgery. The average BMD of the revised hip was higher when compared to the BMD of the contralateral side. ICC was 0.923 for all first and second DEXA scans of the revised hip. When results of individuals with cerclage wires and meshes are excluded, the ICC of the BMD of the revised hip increased to 0.955. Contrary, when only the results of BMD of individuals with cerclage wires and meshes are analyzed, ICC dropped to 0.796.

**Conclusion:** Since cerclage wiring and meshes are frequently used during femoral revision with BIG, DEXA might not be suitable to monitor BMD after femoral revision surgery with BIG.

## BACKGROUND

Hip revision surgery is a challenge to orthopaedic surgeons and bone loss around the primary implant is one of the major problems [1]. Restoration of the bony defects can be done with bone impaction grafting (BIG). BIG for joint replacement surgery has been used with satisfactory results in clinical practice since 1979 for acetabular reconstructions and for femoral reconstructions since 1987 [2-9]. With BIG, first, in case of segmental bone defects, these defects in acetabulum or femur have to be restored with metal meshes. Next, the now cavitory defects are filled with tightly impacted morselized allograft cancellous bone chips in combination with a cemented new prosthesis. The allograft bone serves as a scaffold; new bone can grow into the allograft bone and the allograft bone is resorbed. The allograft bone chips are resorbed by osteoclasts and osteoblasts will form new woven bone. This remodelling of newly formed bone into its characteristic structure will lead to the biological repair of the defect following surgery [10]. From biopsies taken from the acetabular component of patients who had previous hip revision surgery with bone impaction grafting, it is clear that the allograft bone will be almost completely remodeled and incorporated into a new bony structure [11], although this might take several months or even years [12]. Moreover, histology of the bone after bone impaction grafting in hip revision surgery showed that this bone remodeling is slow and that bony healing after hip revision may not be predictable [13, 14]. Absence of balance between the resorption of the allograft bone and the formation of new bone could contribute to stem migration [15].

To understand bone remodeling around primary prosthetic hip implants, several studies used Dual-Energy X-ray Absorptiometry (DEXA) [16-24]. DEXA measures bone mineral density (BMD) in a reproducible, precise and accurate manner and has low radiation exposure to the patient and low costs [23, 25]. Laursen et al. [26] studied experimental defects around acetabular components in human post mortem pelvis specimens. They concluded that DEXA scanning provides a sensitive measure of changes in bone mineral content (BMC) around cementless hemispherical metal-backed cups. However very few studies are known on DEXA and femoral revision surgery with BIG [27].

DEXA might be a tool for quantification of changes in bone content and bone remodeling after revision surgery. Therefore, the use DEXA for femoral bone impaction grafting and bone remodeling after hip revision surgery was evaluated in this study. Another goal of this study was to see whether DEXA can detect and quantify bony defects in the femur, before hip revision surgery.

## METHODS

This study consisted of two parts; first part was a cadaver study in which femoral specimens from cadaver donors were used to determine bone loss of the femur before hip revision and to evaluate steps of hip revision arthroplasty with bone impaction grafting with DEXA. Second part of this study was an observational pilot study in which BMD of the femurs of 13 patients, 1 to 5 years after hip revision surgery with bone impaction grafting, was analysed with DEXA.

### 1. Cadaver study

Ten femoral specimens from cadaver donors and 9 femoral heads from living donors were obtained from Bislife (Leiden, The Netherlands). All donors or family of the donors had given permission for donation and transplantation-related research. Donors were selected and procured according to EU directives for tissue donation [28]. The allograft bone appeared not suitable for donation; however the bone was suitable for transplantation-related research. After donation, tissue was stored at  $-80^{\circ}\text{C}$ .

#### *Procedure*

The femoral heads were morselized in order to obtain cancellous bone chips with a bone mill (Novio Magus bone mill, Spierings Medical Technology, Nijmegen, The Netherlands).

The femurs were thawed; soft tissue was removed and inspected macroscopically for pathology. Then a cascade of operations was done. At several steps, 2 DEXA scans were made and the femur was weighted.

1. The femoral head was resected from the femur.
2. An Exeter prosthesis (Stryker Inc., Newbury, UK) was placed in the proximal femur using standard instruments.
3. A segmental defect was created around the calcar region of the femur, since this is the area in which most defects after primary arthroplasty are found. All ten femoral specimens had different defect sizes.
4. The segmental defect in the femoral cortex was covered with a metal mesh.



5. The femoral canal and the defect were filled with morselized bone chips on top of a bone plug, starting most distally and bone impaction grafting was done.
6. Bone cement was introduced in the femoral canal and the prosthesis was inserted

## 2. Observational pilot study

Thirteen patients with a hip revision surgery for the femoral component or combined femoral/acetabular revision with bone impaction grafting and fixation with cement during the last 5 years at Reinier de Graaf Hospital in Delft, The Netherlands were included in this study. This study was approved by the local Medical Ethics Committee. All patients signed an informed consent before participating in the study.

### *Procedure*

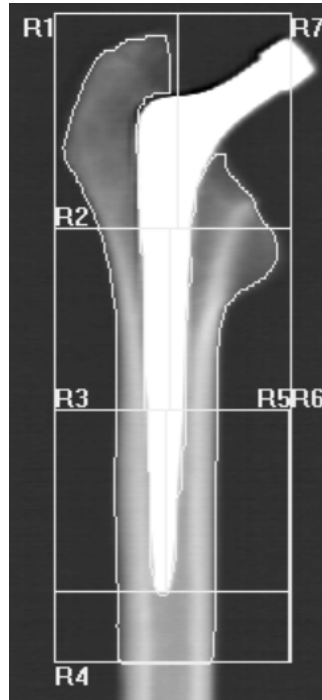All patients received a DEXA scan of the revised hip, the contralateral side and of the lumbar spine. To assess the reproducibility of the measurements, all scans were performed twice, on the same occasion, after being repositioned on the scan table. All DEXA scans were made by one person. The patients were positioned supine on the scan table with the knee of the leg to be scanned supported on a foam positioner. During the DEXA examination the foot of the treated leg was placed in a triangular support in 25 degrees of internal rotation.

Oxford Hip Score (OHS) and Hip disability and Osteoarthritis Outcome Score (HOOS) were scored to evaluate clinical outcomes.

All DEXA scans in both parts of the study were made with a QDR-4500 bone densitometer (Hologic Inc, Bedford, MA, USA) and scans were analyzed using the 7 zones of Gruen [29] (Figure 7.1). Cement was included during DEXA analysis [17]. All measurements were done by the same person.

### **Statistics**

Spearman's Rho was used to determine the relation between the weight-differences of the femur after the defect was created and the corresponding differences in BMD and BMC. Spearman's Rho was also used to calculate the relation between OHS and HOOS. Repeatability was calculated using Cronbach's alpha.



**Figure 7.1** Zones of Gruen in a DEXA image of the cadaver study.

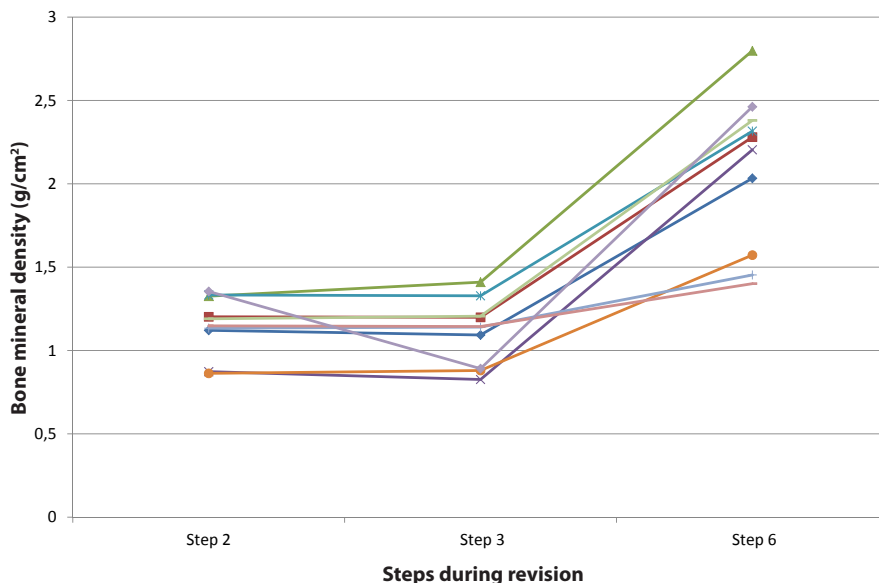
All statistical analyses were performed using IBM SPSS statistics 20.0 (Chicago, Illinois). Differences were considered to be significant at p-values <0.05.

## RESULTS

### 1. Cadaver study

Results of the femoral BMD of Gruen zone 7 after step 2, 3 and 6 for all 10 femoral specimens are shown in Figure 7.2. Mean weight of the created defects was 16.8 g (range 8.5–30.9 g).

No correlation could be found between the weight of the created defects (measured as the difference of the weight of the femur before and after creating the defect) and the BMD- or BMC-differences in Gruen zone 7 ( $p=0.20$  and  $p=0.28$ , respectively). Moreover, no



**Figure 7.2** BMD after step 2, 3 and 6 for ROI 7 for all femoral specimens. Step 2: Femur with prosthesis, step 3: Femur with prosthesis and a defect in the calcar region of the femur. Step 6: Femur at the end of the revision with mesh, bone impaction grafting and cement.

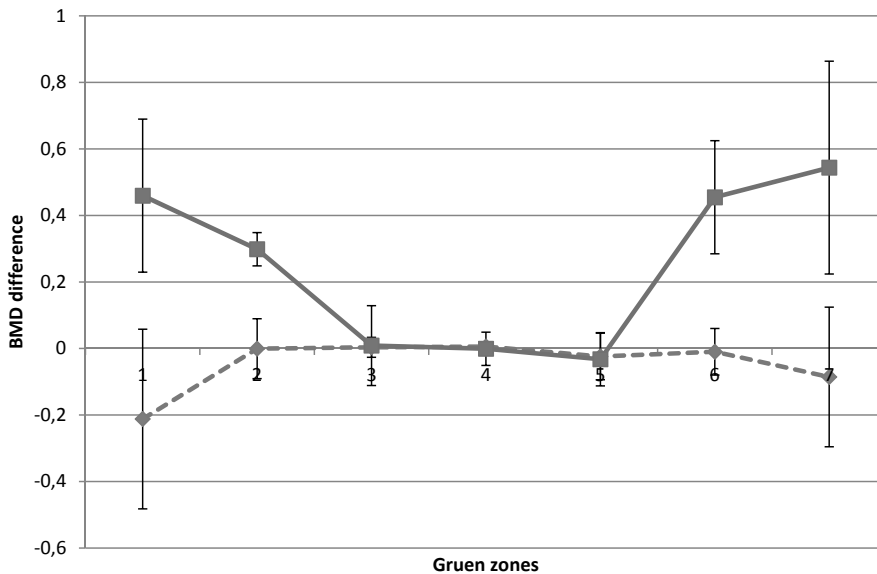
correlation between the weight of the created defects and the BMD- or BMC-differences in Gruen zone 1 was found ( $p=0.60$  and  $p=0.93$  respectively).

The influence of a mesh is shown in Figure 7.3. For all Gruen zones, the mean BMD difference of the femur with and without a defect (BMD after step 3 minus BMD after step 2) is shown and compared to the mean BMD difference when a mesh is included (BMD after step 4 minus BMD after step 2).

Repeatability for all DEXA scans was 1.0 and 0.99 for BMC and BMD respectively.

## 2. Observational pilot study

Thirteen patients, with revision surgery of the hip in combination with bone impaction grafting, matched our criteria. After performing all DEXA scans, one patient was excluded since it was impossible to visualize the bone on the DEXA scan due to the amount of meshes and cerclage wires used during the operation. Therefore 12 patients were used



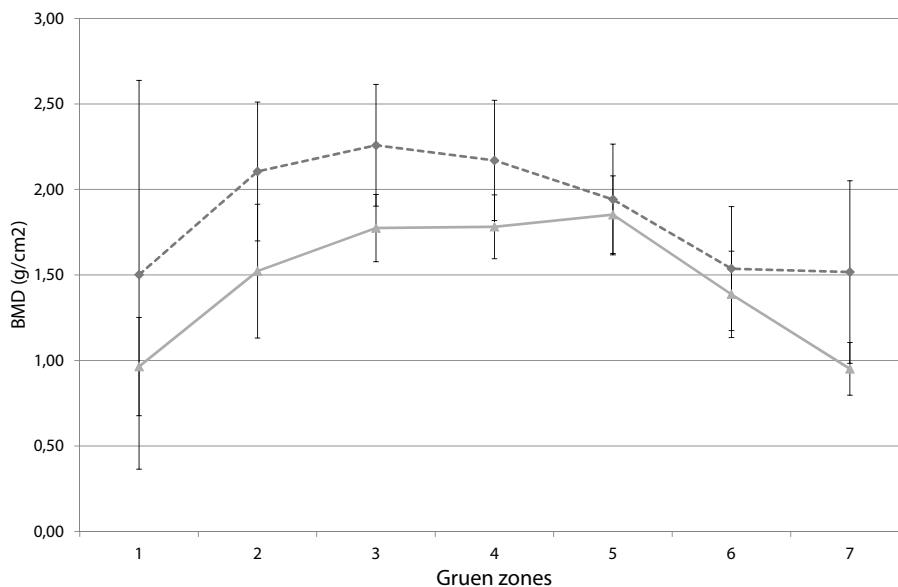
**Figure 7.3** Mean results of BMD all femora of the cadaver study for all Gruen zones, influence of mesh on BMD. The blue line represents the mean BMD difference of the femur with and without a defect (BMD after step 3 minus BMD after step 2). The red line represents the mean BMD difference when a mesh is included (BMD after step 4 minus BMD after step 2).

for evaluation. Mean age was 71.9 ( $\pm 9.5$ ) years. Range of the postoperative scan intervals was 10–63 months after surgery.

The average BMD of the revised hip was higher when compared to the BMD of the contralateral side. This could not be statistically confirmed since only 12 patients were analyzed (Figure 7.4).

ICC was 0.923 for all first and second DEXA scans of the revised hip. When results of individuals with cerclage wires and meshes are excluded, the repeatability of the BMD of the revised hip increased to 0.955. Contrary, when only the results of BMD of individuals with cerclage wires and meshes are analyzed, repeatability dropped to 0.796.

Mean results of the OHS were 36.1 ( $\pm 12.7$ ). Mean HOOS results were 65.8 ( $\pm 23$ ), 62.5 ( $\pm 23$ ), 63.1 ( $\pm 28$ ), 39.0 ( $\pm 34$ ) and 37.0 ( $\pm 32$ ) for subscales pain, symptoms, activity of daily living, sport and recreation function and hip related quality of life respectively.



**Figure 7.4** Mean BMD of the observational pilot study of the 7 Gruen zones of the revised side (blue line) and the contralateral side (red line).

## DISCUSSION

This study evaluated DEXA for the quantification of bony defects in the femur and bone remodeling after hip revision surgery with BIG.

First, a cadaver study was performed. Results showed that the defects created in the femur, in Gruen zone 7, could not be quantified at the DEXA scans. Contrary, Laursen et al. [26] performed a cadaver study in which the defects created in the acetabulum correlated good between the BMC differences measured and the corresponding ash weights of the bone retrieved from the acetabulum. However, their created defects were more standardized when compared to the defects created in our cadaver study.

Results from the cadaver study showed that meshes have a great influence and that the same bone defect, covered with a mesh, results in a totally different BMD and BMC. When the results of the observational pilot study in humans are analyzed, the influence of a mesh on BMD is also shown here. The repeatability of BMD-measurements with DEXA of revised femurs with mesh is greatly reduced when compared to the repeatability of BMD-measurements with DEXA of revised femurs without mesh. Karrholm et al.

[30] performed BMD measurements with DEXA after hip revision surgery with BIG and cement for fixation of the femoral component. They were able to show an increased BMD in most Gruen-zones postoperatively, however they did not use a mesh to cover the defect. Lamberton et al. [1] showed that they used cerclage wiring in more than 50% of all hip revision surgeries with BIG for femoral reinforcement and that a mesh is used in more than 9% of all surgeries.

## Conclusion

Since cerclage wiring and meshes are frequently used during femoral revision with BIG, DEXA might not be suitable to monitor BMD after femoral revision surgery with BIG.

## REFERENCES

1. Lamberton TD, Kenny PJ, Whitehouse SL, Timperley AJ, Gie GA: **Femoral impaction grafting in revision total hip arthroplasty: a follow-up of 540 hips.** *J Arthroplasty* 2011, **26**(8):1154-1160.
2. Schreurs BW, Bolder SB, Gardeniers JW, Verdonschot N, Slooff TJ, Veth RP: **Acetabular revision with impacted morsellised cancellous bone grafting and a cemented cup. A 15- to 20-year follow-up.** *The Journal of bone and joint surgery* 2004, **86**(4):492-497.
3. Schreurs BW, Thien TM, de Waal Malefijt MC, Buma P, Veth RP, Slooff TJ: **Acetabular revision with impacted morselized cancellous bone graft and a cemented cup in patients with rheumatoid arthritis: three to fourteen-year follow-up.** *J Bone Joint Surg Am* 2003, **85-A**(4):647-652.
4. Schreurs BW, Luttjeboer J, Thien TM, de Waal Malefijt MC, Buma P, Veth RP, Slooff TJ: **Acetabular revision with impacted morselized cancellous bone graft and a cemented cup in patients with rheumatoid arthritis. A concise follow-up, at eight to nineteen years, of a previous report.** *J Bone Joint Surg Am* 2009, **91**(3):646-651.
5. Schreurs BW, Slooff TJ, Gardeniers JW, Buma P: **Acetabular reconstruction with bone impaction grafting and a cemented cup: 20 years' experience.** *Clinical orthopaedics and related research* 2001(393):202-215.
6. Schreurs BW, Arts JJ, Verdonschot N, Buma P, Slooff TJ, Gardeniers JW: **Femoral component revision with use of impaction bone-grafting and a cemented polished stem.** *J Bone Joint Surg Am* 2005, **87**(11):2499-2507.
7. Schreurs BW, Arts JJ, Verdonschot N, Buma P, Slooff TJ, Gardeniers JW: **Femoral component revision with use of impaction bone-grafting and a cemented polished stem. Surgical technique.** *J Bone Joint Surg Am* 2006, **88 Suppl 1 Pt 2**:259-274.
8. Slooff TJ, Huiskes R, van Horn J, Lemmens AJ: **Bone grafting in total hip replacement for acetabular protrusion.** *Acta Orthop Scand* 1984, **55**(6):593-596.

9. Gie GA, Linder L, Ling RS, Simon JP, Slooff TJ, Timperley AJ: **Impacted cancellous allografts and cement for revision total hip arthroplasty.** *J Bone Joint Surg Br* 1993, 75(1):14-21.
10. Schreurs BW, Slooff TJ, Buma P, Gardeniers JW, Huiskes R: **Acetabular reconstruction with impacted morsellised cancellous bone graft and cement. A 10- to 15-year follow-up of 60 revision arthroplasties.** *The Journal of bone and joint surgery* 1998, 80(3):391-395.
11. van der Donk S, Buma P, Slooff TJ, Gardeniers JW, Schreurs BW: **Incorporation of morselized bone grafts: a study of 24 acetabular biopsy specimens.** *Clin Orthop Relat Res* 2002(396):131-141.
12. Linder L: **Cancellous impaction grafting in the human femur: histological and radiographic observations in 6 autopsy femurs and 8 biopsies.** *Acta Orthop Scand* 2000, 71(6):543-552.
13. Buma P, Lamerigts N, Schreurs BW, Gardeniers J, Versleyen D, Slooff TJ: **Impacted graft incorporation after cemented acetabular revision. Histological evaluation in 8 patients.** *Acta Orthop Scand* 1996, 67(6):536-540.
14. Ullmark G, Obrant KJ: **Histology of impacted bone-graft incorporation.** *J Arthroplasty* 2002, 17(2):150-157.
15. Tagil M: **The morselized and impacted bone graft. Animal experiments on proteins, impaction and load.** *Acta Orthop Scand Suppl* 2000, 290:1-40.
16. Venesmaa PK, Kroger HP, Jurvelin JS, Miettinen HJ, Suomalainen OT, Alhava EM: **Periprosthetic bone loss after cemented total hip arthroplasty: a prospective 5-year dual energy radiographic absorptiometry study of 15 patients.** *Acta Orthop Scand* 2003, 74(1):31-36.
17. Wilkinson JM, Peel NF, Elson RA, Stockley I, Eastell R: **Measuring bone mineral density of the pelvis and proximal femur after total hip arthroplasty.** *J Bone Joint Surg Br* 2001, 83(2):283-288.
18. Kroger H, Miettinen H, Arnala I, Koski E, Rushton N, Suomalainen O: **Evaluation of periprosthetic bone using dual-energy x-ray absorptiometry: precision of the method and effect of operation on bone mineral density.** *J Bone Miner Res* 1996, 11(10):1526-1530.
19. Damborg F, Nissen N, Jorgensen HR, Abrahamsen B, Brixen K: **Changes in bone mineral density (BMD) around the cemented Exeter stem: a prospective study in 18 women with 5 years follow-up.** *Acta Orthop* 2008, 79(4):494-498.
20. Martini F, Leberherz C, Mayer F, Leichtle U, Kremling E, Sell S: **Precision of the measurements of periprosthetic bone mineral density in hips with a custom-made femoral stem.** *J Bone Joint Surg Br* 2000, 82(7):1065-1071.
21. Okano T, Hagino H, Otsuka T, Teshima R, Yamamoto K, Hirano Y, Nakamura K: **Measurement of periprosthetic bone mineral density by dual-energy x-ray absorptiometry is useful for estimating fixation between the bone and the prosthesis in an early stage.** *J Arthroplasty* 2002, 17(1):49-55.
22. Venesmaa PK, Kroger HP, Miettinen HJ, Jurvelin JS, Suomalainen OT, Alhava EM: **Monitoring of periprosthetic BMD after uncemented total hip arthroplasty with dual-energy X-ray absorptiometry--a 3-year follow-up study.** *J Bone Miner Res* 2001, 16(6):1056-1061.

23. Kilgus DJ, Shimaoka EE, Tipton JS, Eberle RW: **Dual-energy X-ray absorptiometry measurement of bone mineral density around porous-coated cementless femoral implants. Methods and preliminary results.** *J Bone Joint Surg Br* 1993, **75**(2):279-287.
24. Smart RC, Barbagallo S, Slater GL, Kuo RS, Butler SP, Drummond RP, Sekel R: **Measurement of periprosthetic bone density in hip arthroplasty using dual-energy x-ray absorptiometry. Reproducibility of measurements.** *J Arthroplasty* 1996, **11**(4):445-452.
25. Blake GM, Fogelman I: **The clinical role of dual energy X-ray absorptiometry.** *Eur J Radiol* 2009, **71**(3):406-414.
26. Laursen MB, Nielsen PT, Soballe K: **Detection of bony defects around cementless acetabular components in total hip arthroplasty: a DEXA study on 10 human cadavers.** *Acta Orthop* 2006, **77**(2):209-217.
27. Ullmark G, Karrholm J, Sorensen J: **Bone metabolism analyzed by PET and DXA following revision THA using a distally fixed stem. A pilot study.** *Hip Int* 2011, **21**(1):30-38.
28. **Directive 2004/23/EC of the European parliament and of the council of 31 March 2004 on setting standards of quality and safety for the donation, procurement, testing, processing, preservation, storage and distribution of human tissues and cells.** In: *Official Journal of Eur Union*. Edited by Union E, vol. L102; 2004: 48-58.
29. Gruen TA, McNeice GM, Amstutz HC: **"Modes of failure" of cemented stem-type femoral components: a radiographic analysis of loosening.** *Clin Orthop Relat Res* 1979(141):17-27.
30. Karrholm J, Hultmark P, Carlsson L, Malchau H: **Subsidence of a non-polished stem in revisions of the hip using impaction allograft. Evaluation with radiostereometry and dual-energy X-ray absorptiometry.** *J Bone Joint Surg Br* 1999, **81**(1):135-142.



## CHAPTER 8

# GENERAL DISCUSSION

Hip revision arthroplasties are surgical challenging and costly procedures [1]. Restoration of the bone stock deficiency after removal of the primary implant is one of the major problems during the revision procedure. With the bone impaction grafting (BIG) technique the surgeon is able to restore the bony defects in acetabulum and/or femur [2]. Results of BIG are good, but survival rates of the implant after revision surgery with BIG are lower when compared to primary THAs [2-9]. This thesis focused on BIG and how in future the results of hip revision surgery with BIG could be improved by the addition of anti-resorptive drugs and antibiotics to the allograft bone chips which are used during impaction grafting.

### **Loosening and hip revision surgery**

Irrespective to the use of BIG, the incidence of loosening of the prosthesis after hip revision surgery after 2 to 20 years is 19 to 30% of all failures [10-13]. In case of the use of BIG an imbalance between resorption of bone by osteoclasts and formation of new bone by osteoblasts might contribute to early migration and eventually lead to revision of the prosthesis because of loosening. Early migration of stems in hip revision surgery with BIG might be prevented by impregnation of allograft bone with bisphosphonates. In **chapter 3** the results of different locally applied bisphosphonate concentrations in a goat bone chamber model are presented. We concluded that there is a dose-response relation for local application of alendronate with respect to the amount of new bone as well as the amount of non-resorbed bone graft remaining in the bone chamber 12 weeks after implantation. At the optimum dose of 1 mg/mL, the amount of allograft resorption was rather high, but the amount of new bone was high as well, leading to a mixture of graft and new bone with a very high density in the chamber. At a dose of 2 mg/mL, the amount of new bone was less when compared to 1 mg/mL, while resorption percentages appeared to decrease strongly. It has been observed in other studies that by increasing the bisphosphonate concentration, bone metabolism can be blocked completely which might result in decreased implant fixation [14]. It is therefore crucial to have an optimal concentration of the locally applied bisphosphonate leading to a good mix of allograft bone and new bone, which is responsible for fixation strength.

There are several possible explanations for the increase of new bone after 12 weeks in the bisphosphonate groups compared to the control groups. First, the bone present in the bone chamber after 12 weeks is the net result of bone formation and bone resorption during the implantation period. The newly formed bone in the control groups is likely to

be resorbed rapidly again by osteoclasts in this model, which yields a net low amount of new bone after 12 weeks. This has been observed in various other experiments with the same bone chamber model as used in the study of this thesis. Secondly, it was proposed by Jakobsen et al. [15] that the increase in new bone in the bisphosphonate groups might be explained by the prolonged osteoconductive effect of the allograft. Third, in addition to the well described action of bisphosphonates on the inhibition of osteoclasts, it has been demonstrated that administration of particular types of bisphosphonate might stimulate the proliferation of mesenchymal stem cells under certain conditions [16]. Such anabolic effect of (different) bisphosphonates on bone formation is suggested in several *in vitro* [17-21] as well as in one *in vivo* study [22].

In contrast to an increase of new bone after local application of bisphosphonate, at high doses the bisphosphonate might be toxic for osteoblasts and act as a catabolic factor for bone formation, with inhibition of new bone as a result [20, 23]. One explanation for the low amount of new bone formation might be explained by the experimental setup. Allograft bone, impregnated with bisphosphonates, is in several animal studies tested in bone conduction chambers. These bone conduction chambers are very small and totally filled with allograft bone before implantation. If the allograft bone is not resorbed due to the high bisphosphonate concentration, no room is available for new bone formation in the bone conduction chamber. Another explanation for the low amount of new bone formation at high bisphosphonate concentrations might be the toxicity of the bisphosphonate on bone tissue. At a high dose, bisphosphonates are toxic to osteoblast, which inhibits new bone formation [20, 23].

Several other studies presented results on the local administration of bisphosphonates in combination with allograft bone. In **chapter 2** an overview of these studies is presented. Local administration of bisphosphonates in the optimum concentration might play an important role in preventing resorption of the allograft bone by inhibition of the osteoclasts. Therefore, local use of bisphosphonates might improve stability after surgery in which a prosthesis is combined with allograft bone to restore bony defects. However, most of these studies are animal studies. These animal studies differ from the human clinical situation. An important difference is that during hip revision surgery with BIG in humans, cement is used after impaction of the bone graft chips. This cement is pressurized to facilitate cement penetration into the graft. Then, the prosthesis is inserted. During the animal studies no bone cement has been used and therefore, the situation in the bone conduction chamber is not comparable to the clinical situation. A second

difference when the animal studies are compared to the human clinical situation is that most animal studies do not use models where the bone graft is loaded. In humans direct load transfer will take place through the implant-bone interface. In contrast, the allograft bone is placed into a bone conduction chamber without load transfer. Although not many studies investigated the effect of load on the incorporation process of allograft bone, it was demonstrated that the bone that is formed after non-loaded allograft incorporation is less dense than loaded bone graft [24, 25]. Probably the lack of load during incorporation might promote resorption, or, more likely load might be a factor needed for the stimulation of new bone. Irrespective to the cause, the bone chamber model makes it easier to detect potential differences in allograft resorption and new bone formation when bisphosphonate impregnated bone chips are compared with normal bone chips [15].

There is only one study that we know of, in which local application of bisphosphonates is combined with allograft bone and a prosthesis in humans [26]. Results after 24 months were good; impregnation of the allograft bone chips with bisphosphonate prevented resorption and potentially might reduce the risk of mechanical failure, based on the bone mineral density measured with DEXA. This bone mineral density was slightly increased in the bisphosphonate group, while the control group showed a decrease in bone mineral density. However, long term results are not available yet.

In order to stimulate bone formation, we added demineralized bone matrix (DBM) to the allograft bone in the bone chamber study in goats (**chapter 3**). It was hypothesized that the growth factors in the DBM would stimulate osteoblasts. DBM is a product of processed allograft bone and contains collagen, proteins and growth factors [27]. According to literature, demineralization of bone theoretically facilitates the release of growth factors which could increase the bioactivity of the graft and positively influence new bone formation and thus the amount of new bone [28, 29]. However, we were not able to find any differences between bone formation in the bone chamber with and without DBM in goats. Our results confirm the results from several other studies studying the same aspect of bone graft incorporation [30, 31]. However, others have demonstrated an enhancing effect of DBM on bone formation [32, 33]. Bae et al. [34] evaluated the amount of growth factors in different DBM products. They concluded that the quantity of growth factors in all DBM products is low. Moreover, the variability of the concentration of growth factors among different lots of the same DBM product is higher than the variability among different DBM products. They therefore question the efficacy and reliability of DBM. One lot of DBM is made from bone of one donor, which might explain the differences

in growth factors between different lots. However, in our study we used DBM of bone of two different goats and pooled these before use. With pooling, we reduced the risk that the lack of increasing bone formation in the DBM groups could be explained by the differences in BMP-concentration among different lots. However, pooling of bone of two different goats might not be enough, since theoretically both lots might have low amounts of growth factors.

An important reason for the lack of effect of the DBM might have been that the content of growth factors was similar to that in the non-decalcified allograft bone particles. In our bone chamber model the histology showed that the mix of decalcified bone and allograft bone was both resorbed at constant speed. If growth factors would be released during resorption of the graft (irrespective to the demineralization) no effect of DBM could be expected under these experimental conditions.

### Future perspectives of loosening and hip revision

Based on the increasing number of primary hip surgeries, the number of hip revision surgeries is expected to increase [12], and therefore, BIG might be applied more frequently in the future. Understanding the challenges and the variables affecting the outcome of BIG is therefore of great importance.

According to Garcia-Cimbrelo et al. [35], clinical outcome according to the Merle D'Aubigné and Postal score after hip revision surgery with BIG was less successful and subsidence was significantly greater in patients with major bone defects. This is in accordance to the results of Ten Have et al. [9] and of Nelissen et al. [36]; extensive subsidence after BIG occurred mainly in patients with grade IV Endo-Klinik-classified defects (Table 8.1). Gokhale et al. [37] identified prognostic factors for stem and cup

**Table 8.1** Endo-Klinik classification of defects [93]

Grade I	Radiolucent lines confined to the upper half of the cement mantle; clinical signs of loosening
Grade II	Generalized radiolucent zones and endosteal erosion of the upper femur leading to widening of the medullary cavity
Grade III	Widening of the medullary cavity by expansion of the upper femur
Grade IV	Gross destruction of the upper third of the femur with involvement of the middle third, precluding the insertion of even a long-stemmed prosthesis

migration after BIG to restore bone stock in hip revision surgery. They concluded that migration occurred mainly during the first 3 months after surgery. Age, femoral diameter, stem design and density of the graft at the tip of the stem were variables explaining changes in stem alignment. The initial stability of the graft is correlated to the number of impaction blows performed onto the graft [9]. Moreover, the size of the bone graft also determines stability; large grafts might remodel less, resulting in collapse of the graft and possible subsidence [9]. It is unclear what the effect of early weight bearing after surgery is; no differences in migration pattern could be observed between restricted and unrestricted weight bearing after hip revision arthroplasty [38].

If possible predisposing factors for early migration after hip revision surgery with BIG could be identified in individual patients, an intervention with adding bisphosphonates to the bone graft might be prescribed more selectively. However, first the effect of adding bisphosphonates to bone grafts on implant fixation and implant stability has to be studied. Roentgen stereophotogrammetric analysis (RSA) is a frequently used method to measure primary stability of an implant [39]. In RSA, the three-dimensional position and orientation of a prosthesis is determined by the reconstruction of the three-dimensional position of well-defined tantalum markers on the bone and implant. Also, a projected contour of a model of the implant is calculated and matched onto the detected contour of the actual implant in the RSA radiograph [40]. This way, micromotions of the prosthesis with respect to the well-defined markers can be measured. Numerous studies on RSA in hip revision surgery with BIG have been performed [36, 38, 41-46]. It was concluded that the Exeter femoral stem, a standard implant which is also used in hip revision surgery with BIG, showed continued migration. Despite this migration, clinical results are good. Nieuwenhuijse et al. [46] studied the long term RSA results of primary THA with the Exeter stem. They concluded that RSA might be able to predict long-term failure of implants designed to migrate. Therefore, RSA might be an appropriate method for studying the impact on migration when bisphosphonate-impregnated allograft bone chips are used for BIG. In addition, the clinical outcome of the local application of bisphosphonates has to be studied.

## **Infection**

By preventing infections, unnecessary deterioration of the quality of life of the patient as well as a reduction of health care costs might be achieved. Numerous strategies to prevent infection are developed, but the implementation of these measures in clinical

practice varies widely [47]. In this thesis, several measures are discussed, as the use of pre-processed bone chips, impregnation of allograft bone with antibiotics and behavior in the operating theatre.

### **Pre-processed bone chips**

It was hypothesized in **chapter 4** of this thesis that the use of pre-processed bone chips for BIG might reduce bacterial contamination during surgery and as a result, decrease the risk of infection. However, processing of femoral heads in a clean room does not reduce the number of bacteria present on the allograft bone used during the operation. We did not find any difference between the cultures of the femoral heads processed during surgery and the cultures of the bone chips prepared in the clean room. However, bone chips prepared in a clean room before surgery do have several advantages. The preparation of the bone chips during surgery is less time consuming compared with the use of pre-processed bone chips. This time benefit could not be quantified, but is estimated to be approximately 10 to 15 minutes for each femoral head to be processed. Moreover, usage of pre-processed bone chips might be important since pre-processed bone chips are more thoroughly cleaned by rinsing the chips 5 times with saline and thereby washing cells and tissues out of the graft and reducing the immunological reaction. This might result in a better incorporation of the allograft bone after bone impaction grafting [48]. To make a choice between pre-processed bone chips and preparation of bone chips in the operating room, these factors, together with the additional costs, must be considered.

### **Impregnation of allograft bone with antibiotics**

As prophylaxis against infection, bone cements containing antibiotics were developed. These cements may serve as a drug delivery system and make it possible to achieve higher local drug concentrations. However, there is debate on the efficacy of the antibiotic-containing cements [49]. Probably 90% of the antibiotic in the cement will never be released [50]. Only when cracks are formed in the cement layer, a small, sub-therapeutic level of antibiotics will be released into the surrounding tissue. This type of release can continue for years, potentially inducing insufficient bactericidal activity and provide a favorable environment for the cultivation of resistant bacterial strains [50]. Hope et al. [51] noted that of thirty-four patients with joint infection after primary total hip arthroplasty with antibiotic-loaded cement, 88% had at least one resistant bacterial strain. In contrast, a review of Dunbar [52]

showed that antibiotic bone cement has clear efficacy in reducing infection rates in THA. Another preventive measure to reach high local antibiotic concentrations might be the impregnation of allograft bone with antibiotics. In **chapter 5** we confirmed the results of other studies that it is possible to impregnate allograft bone with antibiotics and this way, achieve high local concentrations of the antibiotic, which can serve as a prophylaxis against infection [53-59]. In addition, we showed that the storage of bone chips impregnated with vancomycin or cefazolin at  $-80^{\circ}\text{C}$  does not affect the antibacterial properties. Consequently, the antibiotics can be safely added before surgery which is easier and less time consuming. When compared to antibiotic containing bone cement, Buttaro et al. [60] concluded after studying 57 patients with vancomycin-impregnated allografts to restore the bone stock, that the incidence of deep sepsis was similar to that reported with antibiotic containing bone cement but without the reported pharmacological disadvantages as the release of sub-therapeutic levels of antibiotics.

Local antibiotic therapy has to meet several requirements; the concentration has to be above the minimal inhibitory concentration (MIC) to eradicate bacteria, the concentration used should not be cytotoxic to osteoblasts nor to the bone tissue, drug delivery has to be controlled in order to ensure that known adverse drug reactions like deafness or renal failure are prevented and all of the antibiotics have to be eluted rapidly, especially when used as prophylaxis since small, sub-inhibitory amounts can induce resistance. For prophylaxis, a concentration above the MIC for at least 8 to 10 hours is enough. For therapeutic use, the antibiotic is more effective when the concentration is high and effective (above the MIC) for a longer period, preferably for 2-4 weeks since the diffusion of the antibiotic into the infected tissues takes time, as does the killing of the bacteria. If we look at all these requirements, cefazolin is a good choice for impregnation of allograft bone as prophylaxis [61]. The elution profile shows a high initial release with rapid decay [56]. After three days, all the cefazolin is eluted from the bone chips. Moreover, cefazolin is very effective against *Staphylococcus epidermidis* and *Staphylococcus aureus*, the main pathogens involved in colonizing biomaterials [62]. Vancomycin is another good choice for the impregnation of allograft bone chips. The elution profile is not as steep as that of cefazolin, however vancomycin has low resistance and allergy rate and is also very effective against the pathogens mentioned earlier.

To determine the antibiotic content of the bone chips after impregnation, a dose-response curve for allograft bone impregnated with cefazolin and vancomycin was presented in **chapter 5**. Moreover, in **chapter 3** it was concluded that local use of cefazolin in a high



concentration (a concentration that appeared well above the MIC for *S. epidermidis* in the dose-response curve) does not affect bone remodeling in a goat model. The amount of new bone as well as the amount of graft bone present after 12 weeks was comparable to the amount in the control group, without cefazolin. These results confirm the results of Buttaro et al. [63]. They histologically analysed vancomycin impregnated bone allografts in two hips performed 14 and 20 months after revision surgery with BIG. It was concluded that the histological findings were similar to those reported in allografts without vancomycin and that high levels of vancomycin did not affect the incorporation of the bone graft.

### The operating theatre

Microbiological contamination of air in the operating room is generally considered to be an important risk factor for infection. By monitoring the air in operating theatres, the quality of the air can be evaluated. In **chapter 6** we evaluated the air quality during 70 hip revision surgeries. It was hypothesized that with decreasing the number of door-openings, the air quality measured by the number of CFU/m<sup>3</sup> also decreases, which might lead to a decrease in the infection risk. We did not find a significant association between door-openings and CFU/m<sup>3</sup> in our study ( $p=0.08$ ). However, the odds ratio of door-openings/hour after multivariate analysis was 0.14 (0.02–1.24), meaning that if the number of door-openings/hour increases to more than 4.5, the risk of a number of CFU/m<sup>3</sup> of more than 20 (the HISWPICOT criterion) increases with 7 (1/0.14). The number of surgeries was probably not high enough to detect a significant relation. Moreover, the 95% CI of the odds ratio of door-openings/hour varied greatly, probably because the results of CFU/m<sup>3</sup> varied throughout the surgeries performed. This variation in CFU/m<sup>3</sup> between the different surgeries is in accordance with the results of previous reports [64, 65].

The number of door-openings was very low during the surgeries since doors were only allowed to be opened if strictly necessary. When the number of door-openings/hour is compared to the number of door-openings/hour in other studies, we can confirm that our frequency of door-opening is very low [64, 66-71]. Our results confirm the results of other authors who also reported no significant contribution of door-openings to the number of CFUs/m<sup>3</sup> at the operating room [65, 72]. Contrary, a positive relation was found in several other studies [73-75]. The positive relation between door-openings and the number of CFUs/m<sup>3</sup> might be explained by the turbulent airflow out of the operating room when the operating room door is open. This results in an operating room supplied with unfiltered outdoor air and an increase in microbial contamination [73].

We were not able to show a correlation between number of CFU/m<sup>3</sup>, particles and CFU/m<sup>2</sup>/hour on the sedimentation plate. These results confirm the results of several other studies [76, 77], although some authors did find a significant correlation [78]. Different variables are measured with the different methods: sedimentation plates are used for passive sampling and might provide best insight in the number of bacteria settling on surfaces, volumetric sampling of the number of CFU/m<sup>3</sup> is active sampling to obtain information on the number of bacteria in the air, while particle measurements (active sampling) provides information on the number of dust particles in the operating room. This might explain the varying results, since these variables might differ throughout the hospitals or even throughout the same operating room since different factors influence the results, as the frequency of door-opening [78, 79]. At this moment no international consensus on what method to be used for routine air monitoring is available [73]; there is still debate on the sampling techniques to be used, their frequency of application and even on the usefulness of such checks and controls. International standards offer different techniques (active through air samplers or passive sampling through sedimentation plates) and different kinds of samplers, thus leaving the choice of system open [78].

According to Andersson et al. [80], the duration of the surgery is of clinical relevance since the total CFU level increases with increasing duration of the surgery, thereby exposing the wound to an increased total number of CFUs and as a consequence increasing the risk of infection. This result was confirmed by Ong et al. [81]. However, we were not able to show an association between the numbers of CFU and the operation time. In addition, no relation between the number of people present at the operating theatre and the number of CFU at the operating theatre could be found.

### **Future perspectives of infection and hip revision surgery**

The etiology of infection is multifactorial. Identifying risk factors for the individual patient and optimizing medical management of the conditions seems therefore important [82]. Pulido et al. [83] identified several risk factors for the development of a periprosthetic joint infection; patient related factors included a BMI of more than 40 kg/m<sup>2</sup>, an American Society Of anesthesiologists score (ASA) of more than 2 and postoperative atrial fibrillation, myocardial infarction and urinary tract infection. The influence of preexisting comorbidities on periprosthetic joint infection was confirmed by Ong et al. [81]. Bozic et al. [82] further specified these preexisting comorbidities. They concluded that rheumatologic disease, obesity, coagulopathy and preoperative anemia were

associated with an increased risk of periprosthetic joint infection. Moreover, Malinzak et al. [84] also stated that patient comorbidities as obesity and diabetes significantly affect the infection risk. The information from these studies is important to consider when discussing the risks associated with total hip arthroplasty in patients with preexisting comorbidities. Medical management of these conditions should be optimized prior to considering elective total hip arthroplasty in this patient population [82].

Usage of antibiotic-impregnated allograft bone for BIG might be a good option for prophylaxis. When we take a close look at the requirements for local antibiotic prophylaxis, we can conclude that the impregnation of bone allograft with cefazolin or vancomycin meets those requirements and that it might be a good alternative for bone cement to achieve high local antibiotic concentrations. However, it is likely that it will only be a matter of time before bacteria develop a mechanism of resistance against any new locally applied antibiotic. Therefore, further research into the use of combinations of antibiotics, i.e. multidrug targeting, has to be performed [85].

### **Imaging of bone remodeling**

Since the introduction of BIG, there has been a debate whether the impacted bone graft actually integrates into the surrounding host bone. Biopsies obtained from the impacted area have suggested that the allograft is in time replaced with new bone [86, 87]. Although clinical radiographs also provide some evidence for re-trabeculation and thus incorporation of the graft, reliable information regarding the amount of incorporated allograft is missing. In **chapter 7** of this thesis we evaluated DEXA for the quantification of bone remodeling after hip revision surgery with BIG. It was concluded that the use of meshes to reconstruct the defect in combination with BIG, makes DEXA less reproducible and therefore not usable.

### **Future perspectives of imaging of bone remodelling**

Since obtaining biopsies can compromise the healing and introduces a risk of infection or fracture, a method other than DEXA for documenting the healing process of the allograft bone has to be studied. Positron emission tomography (PET) showed to be a sensitive method for evaluating neovascularisation and bone formation in impacted morsellized allografts [88, 89]. It was concluded that after 6 years, the metabolism of the allografted bone had normalized compared to native bone. Although not studied in revised hips with

BIG, PET/CT might even be a better method to determine metabolic bone responses [90]. Bone scintigraphy might be another possibility to study new bone formation in a non-invasive way. The use of bone scintigraphy was evaluated by Tokgozoglu et al. [91] and Hisatome et al. [92]. Both studies showed an intense radionuclide uptake in the area corresponding to the graft material, which might be an indicator of new bone formation and revascularization of the allograft. Therefore, bone scintigraphy might be suitable for gaining insight in the process of remodeling of the allograft bone in BIG.

## General conclusion

It can be concluded that there is a dose-response relation for local application of alendronate with respect to the amount of new bone as well as the amount of non-resorbed bone graft. Therefore, local administration of bisphosphonates in the optimum concentration might play an important role in improving stability after surgery in which a prosthesis is combined with allograft bone to restore bony defects. If possible predisposing factors for early migration after hip revision surgery with BIG could be identified in the individual patient, local application of bisphosphonates should be applied selectively. However, more research has to be done to study the effect of local use in patients.

Impregnation of allograft bone with antibiotics can be used to reach efficient high local antibiotic concentrations and serve as a prophylaxis against infection. Pre-processed bone chips for BIG have similar levels of microbiological contamination when compared to femoral heads morselized during surgery, however pre-processed bone chips will be incorporated better and they are more easily used during surgery.

The frequency of door-openings during surgery is correlated to the microbiological contamination (CFU/m<sup>3</sup>) of the operating room. Therefore, to prevent infection, door-openings during surgery should be kept at a minimum. The duration of the surgery and the number of people present during surgery were not correlated to the microbiological contamination during surgery.

The use of meshes to reconstruct a defect during BIG ensures a DEXA scan less reproducible. For the quantification of bone remodeling after hip revision surgery with BIG, another method has to be used.

## REFERENCES

1. Lie SA, Havelin LI, Furnes ON, Engesaeter LB, Vollset SE: **Failure rates for 4762 revision total hip arthroplasties in the Norwegian Arthroplasty Register.** *J Bone Joint Surg Br* 2004, **86**(4):504-509.
2. Schreurs BW, Arts JJ, Verdonschot N, Buma P, Slooff TJ, Gardeniers JW: **Femoral component revision with use of impaction bone-grafting and a cemented polished stem. Surgical technique.** *J Bone Joint Surg Am* 2006, **88 Suppl 1 Pt 2**:259-274.
3. Schreurs BW, Arts JJ, Verdonschot N, Buma P, Slooff TJ, Gardeniers JW: **Femoral component revision with use of impaction bone-grafting and a cemented polished stem.** *J Bone Joint Surg Am* 2005, **87**(11):2499-2507.
4. Schreurs BW, Gardeniers JW, Slooff TJ: **Acetabular reconstruction with bone impaction grafting: 20 years of experience.** *Instr Course Lect* 2001, **50**:221-228.
5. van Egmond N, De Kam DC, Gardeniers JW, Schreurs BW: **Revisions of extensive acetabular defects with impaction grafting and a cement cup.** *Clin Orthop Relat Res* 2011, **469**(2):562-573.
6. te Stroet MA, Gardeniers JW, Verdonschot N, Rijnen WH, Slooff TJ, Schreurs BW: **Femoral component revision with use of impaction bone-grafting and a cemented polished stem: a concise follow-up, at fifteen to twenty years, of a previous report.** *J Bone Joint Surg Am* 2012, **94**(23):e1731-1734.
7. Busch VJ, Gardeniers JW, Verdonschot N, Slooff TJ, Schreurs BW: **Acetabular reconstruction with impaction bone-grafting and a cemented cup in patients younger than fifty years old: a concise follow-up, at twenty to twenty-eight years, of a previous report.** *J Bone Joint Surg Am* 2011, **93**(4):367-371.
8. Garvin KL, Konigsberg BS, Ommen ND, Lyden ER: **What is the Long-term Survival of Impaction Allografting of the Femur?** *Clin Orthop Relat Res* 2013.
9. Ten Have BL, Brouwer RW, van Biezen FC, Verhaar JA: **Femoral revision surgery with impaction bone grafting: 31 hips followed prospectively for ten to 15 years.** *J Bone Joint Surg Br* 2012, **94**(5):615-618.
10. Springer BD, Fehring TK, Griffin WL, Odum SM, Masonis JL: **Why revision total hip arthroplasty fails.** *Clin Orthop Relat Res* 2009, **467**(1):166-173.
11. Lamberton TD, Kenny PJ, Whitehouse SL, Timperley AJ, Gie GA: **Femoral impaction grafting in revision total hip arthroplasty: a follow-up of 540 hips.** *J Arthroplasty* 2011, **26**(8):1154-1160.
12. Bozic KJ, Kurtz SM, Lau E, Ong K, Vail TP, Berry DJ: **The epidemiology of revision total hip arthroplasty in the United States.** *J Bone Joint Surg Am* 2009, **91**(1):128-133.
13. Jafari SM, Coyle C, Mortazavi SM, Sharkey PF, Parvizi J: **Revision hip arthroplasty: infection is the most common cause of failure.** *Clin Orthop Relat Res* 2010, **468**(8):2046-2051.
14. Baas J, Elmengaard B, Jensen TB, Jakobsen T, Andersen NT, Soballe K: **The effect of pretreating morselized allograft bone with rhBMP-2 and/or pamidronate on the fixation of porous Ti and HA-coated implants.** *Biomaterials* 2008, **29**(19):2915-2922.

15. Jakobsen T, Baas J, Bechtold JE, Elmengaard B, Soballe K: **The effect of soaking allograft in bisphosphonate: a pilot dose-response study.** *Clin Orthop Relat Res* 2010, **468**(3):867-874.
16. von Knoch F, Jaquiere C, Kowalsky M, Schaeren S, Alabre C, Martin I, Rubash HE, Shanbhag AS: **Effects of bisphosphonates on proliferation and osteoblast differentiation of human bone marrow stromal cells.** *Biomaterials* 2005, **26**(34):6941-6949.
17. Ozturk AM, Tabak AY, Aktekin CN, Altay M, Erdemli E, Karahuseyinoglu S, Korkusuz F: **Alendronate enhances antibiotic-impregnated bone grafts in the treatment of osteomyelitis.** *Int Orthop* 2008, **32**(6):821-827.
18. Im GI, Qureshi SA, Kenney J, Rubash HE, Shanbhag AS: **Osteoblast proliferation and maturation by bisphosphonates.** *Biomaterials* 2004, **25**(18):4105-4115.
19. Reinholz GG, Getz B, Pederson L, Sanders ES, Subramaniam M, Ingle JN, Spelsberg TC: **Bisphosphonates directly regulate cell proliferation, differentiation, and gene expression in human osteoblasts.** *Cancer Res* 2000, **60**(21):6001-6007.
20. Gangoiti MV, Cortizo AM, Arnol V, Felice JI, McCarthy AD: **Opposing effects of bisphosphonates and advanced glycation end-products on osteoblastic cells.** *Eur J Pharmacol* 2008, **600**(1-3):140-147.
21. Naidu A, Dechow PC, Spears R, Wright JM, Kessler HP, Opperman LA: **The effects of bisphosphonates on osteoblasts in vitro.** *Oral Surg Oral Med Oral Pathol Oral Radiol Endod* 2008, **106**(1):5-13.
22. von Knoch F, Eckhardt C, Alabre CI, Schneider E, Rubash HE, Shanbhag AS: **Anabolic effects of bisphosphonates on peri-implant bone stock.** *Biomaterials* 2007, **28**(24):3549-3559.
23. Orriss IR, Key ML, Colston KW, Arnett TR: **Inhibition of osteoblast function in vitro by aminobisphosphonates.** *J Cell Biochem* 2009, **106**(1):109-118.
24. Lamerigts NM, Buma P, Huiskes R, Schreurs W, Gardeniers J, Slooff TJ: **Incorporation of morsellized bone graft under controlled loading conditions. A new animal model in the goat.** *Biomaterials* 2000, **21**(7):741-747.
25. Wang JS, Tagil M, Aspenberg P: **Load-bearing increases new bone formation in impacted and morselized allografts.** *Clin Orthop Relat Res* 2000(378):274-281.
26. Kesteris U, Aspenberg P: **Rinsing morsellized bone grafts with bisphosphonate solution prevents their resorption. A prospective randomised double-blinded study.** *J Bone Joint Surg Br* 2006, **88**(8):993-996.
27. Watson JT: **Overview of biologics.** *J Orthop Trauma* 2005, **19**(10 Suppl):S14-16.
28. Wildemann B, Kadow-Romacker A, Haas NP, Schmidmaier G: **Quantification of various growth factors in different demineralized bone matrix preparations.** *J Biomed Mater Res A* 2007, **81**(2):437-442.
29. Shih HN, Shih LY, Sung TH, Chang YC: **Restoration of bone defect and enhancement of bone ingrowth using partially demineralized bone matrix and marrow stromal cells.** *J Orthop Res* 2005, **23**(6):1293-1299.
30. Becker W, Urist MR, Tucker LM, Becker BE, Ochsnein C: **Human demineralized freeze-dried bone: inadequate induced bone formation in athymic mice. A preliminary report.** *J Periodontol* 1995, **66**(9):822-828.

31. Intini G, Andreana S, Buhite RJ, Bobek LA: **A comparative analysis of bone formation induced by human demineralized freeze-dried bone and enamel matrix derivative in rat calvaria critical-size bone defects.** *J Periodontol* 2008, **79**(7):1217-1224.
32. Schwartz Z, Mellonig JT, Carnes DL, Jr., de la Fontaine J, Cochran DL, Dean DD, Boyan BD: **Ability of commercial demineralized freeze-dried bone allograft to induce new bone formation.** *J Periodontol* 1996, **67**(9):918-926.
33. Schwartz Z, Somers A, Mellonig JT, Carnes DL, Jr., Dean DD, Cochran DL, Boyan BD: **Ability of commercial demineralized freeze-dried bone allograft to induce new bone formation is dependent on donor age but not gender.** *J Periodontol* 1998, **69**(4):470-478.
34. Bae HW, Zhao L, Kanim LE, Wong P, Delamarter RB, Dawson EG: **Intervariability and intravariability of bone morphogenetic proteins in commercially available demineralized bone matrix products.** *Spine (Phila Pa 1976)* 2006, **31**(12):1299-1306; discussion 1307-1298.
35. Garcia-Cimbrello E, Garcia-Rey E, Cruz-Pardos A: **The extent of the bone defect affects the outcome of femoral reconstruction in revision surgery with impacted bone grafting: a five- to 17-year follow-up study.** *J Bone Joint Surg Br* 2011, **93**(11):1457-1464.
36. Nelissen RG, Valstar ER, Poll RG, Garling EH, Brand R: **Factors associated with excessive migration in bone impaction hip revision surgery: a radiostereometric analysis study.** *J Arthroplasty* 2002, **17**(7):826-833.
37. Gokhale S, Soliman A, Dantas JP, Richardson JB, Cook F, Kuiper JH, Jones P: **Variables affecting initial stability of impaction grafting for hip revision.** *Clin Orthop Relat Res* 2005(432):174-180.
38. Ornstein E, Franzen H, Johnsson R, Stefansdottir A, Sundberg M, Tagil M: **Hip revision with impacted morselized allografts: unrestricted weight-bearing and restricted weight-bearing have similar effect on migration. A radiostereometry analysis.** *Arch Orthop Trauma Surg* 2003, **123**(6):261-267.
39. Selvik G: **Roentgen stereophotogrammetry. A method for the study of the kinematics of the skeletal system.** *Acta Orthop Scand Suppl* 1989, **232**:1-51.
40. Valstar ER, de Jong FW, Vrooman HA, Rozing PM, Reiber JH: **Model-based Roentgen stereophotogrammetry of orthopaedic implants.** *J Biomech* 2001, **34**(6):715-722.
41. Ornstein E, Franzen H, Johnsson R, Sundberg M: **Radiostereometric analysis in hip revision surgery--optimal time for index examination: 6 patients revised with impacted allografts and cement followed weekly for 6 weeks.** *Acta Orthop Scand* 2000, **71**(4):360-364.
42. Ornstein E, Franzen H, Johnsson R, Sandquist P, Stefansdottir A, Sundberg M: **Migration of the acetabular component after revision with impacted morselized allografts: a radiostereometric 2-year follow-up analysis of 21 cases.** *Acta Orthop Scand* 1999, **70**(4):338-342.
43. Ornstein E, Atroshi I, Franzen H, Johnsson R, Sandquist P, Sundberg M: **Results of hip revision using the Exeter stem, impacted allograft bone, and cement.** *Clin Orthop Relat Res* 2001(389):126-133.



44. Ornstein E, Franzen H, Johnsson R, Stefansdottir A, Sundberg M, Tagil M: **Five-year follow-up of socket movements and loosening after revision with impacted morselized allograft bone and cement: a radiostereometric and radiographic analysis.** *J Arthroplasty* 2006, **21**(7):975-984.
45. Ornstein E, Franzen H, Johnsson R, Karlsson MK, Linder L, Sundberg M: **Hip revision using the Exeter stem, impacted morselized allograft bone and cement: a consecutive 5-year radiostereometric and radiographic study in 15 hips.** *Acta Orthop Scand* 2004, **75**(5):533-543.
46. Nieuwenhuijse MJ, Valstar ER, Kaptein BL, Nelissen RG: **The Exeter femoral stem continues to migrate during its first decade after implantation: 10-12 years of follow-up with radiostereometric analysis (RSA).** *Acta Orthop* 2012, **83**(2):129-134.
47. Merollini KM, Crawford RW, Whitehouse SL, Graves N: **Surgical site infection prevention following total hip arthroplasty in Australia: A cost-effectiveness analysis.** *Am J Infect Control* 2013.
48. van der Donk S, Weernink T, Buma P, Aspenberg P, Slooff TJ, Schreurs BW: **Rinsing morselized allografts improves bone and tissue ingrowth.** *Clin Orthop Relat Res* 2003(408):302-310.
49. van de Belt H, Neut D, Schenk W, van Horn JR, van der Mei HC, Busscher HJ: **Infection of orthopedic implants and the use of antibiotic-loaded bone cements. A review.** *Acta Orthop Scand* 2001, **72**(6):557-571.
50. Winkler H, Kaudela K, Stoiber A, Menschik F: **Bone grafts impregnated with antibiotics as a tool for treating infected implants in orthopedic surgery - one stage revision results.** *Cell and tissue banking* 2006, **7**(4):319-323.
51. Hope PG, Kristinsson KG, Norman P, Elson RA: **Deep infection of cemented total hip arthroplasties caused by coagulase-negative staphylococci.** *J Bone Joint Surg Br* 1989, **71**(5):851-855.
52. Dunbar MJ: **Antibiotic bone cements: their use in routine primary total joint arthroplasty is justified.** *Orthopedics* 2009, **32**(9).
53. Witso E, Persen L, Benum P, Bergh K: **Release of netilmicin and vancomycin from cancellous bone.** *Acta Orthop Scand* 2002, **73**(2):199-205.
54. Witso E, Persen L, Benum P, Aamodt A, Husby OS, Bergh K: **High local concentrations without systemic adverse effects after impaction of netilmicin-impregnated bone.** *Acta Orthop Scand* 2004, **75**(3):339-346.
55. Winkler H, Janata O, Berger C, Wein W, Georgopoulos A: **In vitro release of vancomycin and tobramycin from impregnated human and bovine bone grafts.** *J Antimicrob Chemother* 2000, **46**(3):423-428.
56. Witso E, Persen L, Loseth K, Benum P, Bergh K: **Cancellous bone as an antibiotic carrier.** *Acta Orthop Scand* 2000, **71**(1):80-84.
57. Witso E, Persen L, Benum P, Bergh K: **Cortical allograft as a vehicle for antibiotic delivery.** *Acta Orthop* 2005, **76**(4):481-486.



58. Buttaro MA, Gimenez MI, Greco G, Barcan L, Piccaluga F: **High active local levels of vancomycin without nephrotoxicity released from impacted bone allografts in 20 revision hip arthroplasties.** *Acta Orthop* 2005, **76**(3):336-340.
59. Buttaro MA, Gonzalez Della Valle AM, Pineiro L, Mocetti E, Morandi AA, Piccaluga F: **Incorporation of vancomycin-supplemented bone incorporation of vancomycin-supplemented bone allografts: radiographical, histopathological and immunohistochemical study in pigs.** *Acta Orthop Scand* 2003, **74**(5):505-513.
60. Buttaro MA, Guala AJ, Comba F, Suarez F, Piccaluga F: **Incidence of deep infection in aseptic revision THA using vancomycin-impregnated impacted bone allograft.** *Hip Int* 2010, **20**(4):535-541.
61. Illingworth KD, Mihalko WM, Parvizi J, Sculco T, McArthur B, Bitar YE, Saleh KJ: **How to Minimize Infection and Thereby Maximize Patient Outcomes in Total Joint Arthroplasty: A Multicenter Approach: AAOS Exhibit Selection.** *J Bone Joint Surg Am* 2013, **95**(8):e501-513.
62. Montanaro L, Arciola CR, Baldassarri L, Borsetti E: **Presence and expression of collagen adhesin gene (cna) and slime production in Staphylococcus aureus strains from orthopaedic prosthesis infections.** *Biomaterials* 1999, **20**(20):1945-1949.
63. Buttaro MA, Morandi A, Rivello HG, Piccaluga F: **Histology of vancomycin-supplemented impacted bone allografts in revision total hip arthroplasty.** *J Bone Joint Surg Br* 2005, **87**(12):1684-1687.
64. Andersson AE, Bergh I, Karlsson J, Eriksson BI, Nilsson K: **Traffic flow in the operating room: An explorative and descriptive study on air quality during orthopedic trauma implant surgery.** *Am J Infect Control* 2012.
65. Stocks GW, Self SD, Thompson B, Adame XA, O'Connor DP: **Predicting bacterial populations based on airborne particulates: a study performed in nonlaminar flow operating rooms during joint arthroplasty surgery.** *Am J Infect Control* 2010, **38**(3):199-204.
66. Lynch RJ, Englesbe MJ, Sturm L, Bitar A, Budhiraj K, Kolla S, Polyachenko Y, Duck MG, Campbell DA, Jr.: **Measurement of foot traffic in the operating room: implications for infection control.** *Am J Med Qual* 2009, **24**(1):45-52.
67. Panahi P, Stroh M, Casper DS, Parvizi J, Austin MS: **Operating Room Traffic is a Major Concern During Total Joint Arthroplasty.** *Clin Orthop Relat Res* 2012.
68. Panahi P, Stroh M, Casper DS, Parvizi J, Austin MS: **Operating room traffic is a major concern during total joint arthroplasty.** *Clin Orthop Relat Res* 2012, **470**(10):2690-2694.
69. Parikh SN, Grice SS, Schnell BM, Salisbury SR: **Operating room traffic: is there any role of monitoring it?** *J Pediatr Orthop* 2010, **30**(6):617-623.
70. Young RS, O'Regan DJ: **Cardiac surgical theatre traffic: time for traffic calming measures?** *Interact Cardiovasc Thorac Surg* 2010, **10**(4):526-529.
71. Pryor F, Messmer PR: **The effect of traffic patterns in the OR on surgical site infections.** *AORN J* 1998, **68**(4):649-660.
72. Ritter MA, Eitzen H, French ML, Hart JB: **The operating room environment as affected by people and the surgical face mask.** *Clin Orthop Relat Res* 1975(111):147-150.

73. Scaltriti S, Cencetti S, Rovesti S, Marchesi I, Bargellini A, Borella P: **Risk factors for particulate and microbial contamination of air in operating theatres.** *J Hosp Infect* 2007, **66**(4):320-326.
74. Ritter MA: **Operating room environment.** *Clin Orthop Relat Res* 1999(369):103-109.
75. Matar WY, Jafari SM, Restrepo C, Austin M, Purtill JJ, Parvizi J: **Preventing infection in total joint arthroplasty.** *J Bone Joint Surg Am* 2010, **92** Suppl 2:36-46.
76. Cristina ML, Spagnolo AM, Sartini M, Panatto D, Gasparini R, Orlando P, Ottria G, Perdelli F: **Can particulate air sampling predict microbial load in operating theatres for arthroplasty?** *PLoS One* 2012, **7**(12):e52809.
77. Landrin A, Bissery A, Kac G: **Monitoring air sampling in operating theatres: can particle counting replace microbiological sampling?** *J Hosp Infect* 2005, **61**(1):27-29.
78. Napoli C, Marcotrigiano V, Montagna MT: **Air sampling procedures to evaluate microbial contamination: a comparison between active and passive methods in operating theatres.** *BMC Public Health* 2012, **12**:594.
79. Dharan S, Pittet D: **Environmental controls in operating theatres.** *J Hosp Infect* 2002, **51**(2):79-84.
80. Andersson AE, Bergh I, Karlsson J, Eriksson BI, Nilsson K: **Traffic flow in the operating room: an explorative and descriptive study on air quality during orthopedic trauma implant surgery.** *Am J Infect Control* 2012, **40**(8):750-755.
81. Ong KL, Kurtz SM, Lau E, Bozic KJ, Berry DJ, Parvizi J: **Prosthetic joint infection risk after total hip arthroplasty in the Medicare population.** *J Arthroplasty* 2009, **24**(6 Suppl):105-109.
82. Bozic KJ, Lau E, Kurtz S, Ong K, Rubash H, Vail TP, Berry DJ: **Patient-related risk factors for periprosthetic joint infection and postoperative mortality following total hip arthroplasty in Medicare patients.** *J Bone Joint Surg Am* 2012, **94**(9):794-800.
83. Pulido L, Ghanem E, Joshi A, Purtill JJ, Parvizi J: **Periprosthetic joint infection: the incidence, timing, and predisposing factors.** *Clin Orthop Relat Res* 2008, **466**(7):1710-1715.
84. Malinzak RA, Ritter MA, Berend ME, Meding JB, Olberding EM, Davis KE: **Morbidly obese, diabetic, younger, and unilateral joint arthroplasty patients have elevated total joint arthroplasty infection rates.** *J Arthroplasty* 2009, **24**(6 Suppl):84-88.
85. Murray PR, Rosenthal KS, Kobayashi GS, Pfaller MA: **Medical Microbiology**, 3 edn. St. Louis: Mosby; 1998.
86. Buma P, Lamerigts N, Schreurs BW, Gardeniers J, Versleyen D, Slooff TJ: **Impacted graft incorporation after cemented acetabular revision. Histological evaluation in 8 patients.** *Acta Orthop Scand* 1996, **67**(6):536-540.
87. Ullmark G, Obrant KJ: **Histology of impacted bone-graft incorporation.** *J Arthroplasty* 2002, **17**(2):150-157.
88. Sorensen J, Ullmark G, Langstrom B, Nilsson O: **Rapid bone and blood flow formation in impacted morselized allografts: positron emission tomography (PET) studies on allografts in 5 femoral component revisions of total hip arthroplasty.** *Acta Orthop Scand* 2003, **74**(6):633-643.

89. Ullmark G, Sorensen J, Langstrom B, Nilsson O: **Bone regeneration 6 years after impaction bone grafting: a PET analysis.** *Acta Orthop* 2007, **78**(2):201-205.
90. Ullmark G, Nilsson O, Maripuu E, Sorensen J: **Analysis of bone mineralization on uncemented femoral stems by [18F]-fluoride-PET: a randomized clinical study of 16 hips in 8 patients.** *Acta Orthop* 2013, **84**(2):138-144.
91. Mazhar Tokgozoglu A, Aydin M, Atilla B, Caner B: **Scintigraphic evaluation of impaction grafting for total hip arthroplasty revision.** *Arch Orthop Trauma Surg* 2000, **120**(7-8):416-419.
92. Hisatome T, Yasunaga Y, Takahashi K, Ochi M: **Bone remodeling after impacted cancellous allograft in revision hip arthroplasty based on (99m)Tc-MDP bone scintigraphy.** *Arch Orthop Trauma Surg* 2004, **124**(1):52-55.
93. Gie GA, Linder L, Ling RS, Simon JP, Slooff TJ, Timperley AJ: **Impacted cancellous allografts and cement for revision total hip arthroplasty.** *J Bone Joint Surg Br* 1993, **75**(1):14-21.



**ENGLISH SUMMARY**  
**NEDERLANDSE SAMENVATTING**  
**DANKWOORD**  
**CURRICULUM VITAE**

## ENGLISH SUMMARY

Mechanical loosening is one of the most common causes of failure of a primary total hip arthroplasty (THA) and occurs secondary to a chronic, granulomatous, inflammatory response that is stimulated and maintained by implant-derived wear particles. This process is complex and might lead to a localized or systemic reduction in bone mass. After failure of a primary THA, a more challenging and costly hip revision surgery is needed. One of the techniques to restore the bone stock around the implant during hip revision surgery is bone impaction grafting (BIG). With BIG, first, bony defects in acetabulum and femur can be restored with metal meshes in order to recreate a contained defect. Next, these defects are filled with tightly impacted morselized allograft cancellous bone chips in combination with a cemented new prosthesis. The allograft bone serves as a scaffold; new blood vessels and woven bone can grow into the allograft bone and during this process the allograft bone is resorbed by osteoclasts. Remodelling of the newly formed immature bone into its characteristic mature bony structure will lead to a biological repair of the defect.

This thesis focused on BIG and how in the future the results of hip revision surgery with BIG could be improved by treatment of the allograft bone chips which are used during impaction grafting.

### Loosening and hip revision surgery

Nineteen to thirty percent of all failures after revision surgery are caused by loosening of the prosthesis. When allograft or autograft bone tissue is being used, the coupling between osteoblast and osteoclast function is less organized. Therefore it might lead to faster resorption in relation to bone deposition. In the case of BIG this may lead to destabilization of the implant. This mechanical weakness might result in loosening of the prosthesis. To optimize the balance between bone resorption and bone formation bisphosphonates might be used.

Several studies have been performed on the local application of bisphosphonates in combination with allograft bone, however results vary greatly. An overview of all studies combining bisphosphonates with allograft bone is presented in **chapter 2** of this thesis. Local administration of bisphosphonates in the optimum concentration might play an important role in preventing resorption of the allograft bone by inhibition of the osteoclasts. Therefore, local use of bisphosphonates might improve stability after surgery in which a prosthesis is combined with allograft bone to restore bony defects.

In **chapter 3** the results of a bone chamber study in goats are presented. We conclude that there is a dose-response relation for local application of alendronate with respect to the amount of new bone as well as the amount of non-resorbed bone graft remaining in the bone chamber 12 weeks after implantation. In order to stimulate bone formation, we also added DBM to the allograft bone. It was hypothesized that the growth factors in the DBM would stimulate osteoblasts. However, we were not able to find any differences between bone formation in the bone chamber with and without DBM in goats.

### **Infection and hip revision surgery**

Nowadays, infections occur in approximately 0.5 to 3% of all primary THAs and after revision THA, these percentages are higher and range from 4 to 6%. Infection is a potentially devastating complication; patients may require further surgery, additional nursing care and in extreme cases it is followed by the death of the patient. Reducing the risk of infection is a major challenge that deserves continued attention. It is important to understand etiology and risk factors for infection to be able to prevent and reduce infection rates.

The use of allograft bone chips for BIG introduces a potential source of infection. In most cases, the allograft bone which is used for BIG, is prepared in the operating theatre during surgery just prior to use. The preparation of bone chips in the operation room takes about ten minutes, it necessitates the use of special instrument such as a bone mill and due to the limited area in a down flow plenum system, an enclosed space inside the operating theatre with laminar air flow, the preparation of bone chips often takes place outside the plenum. However, the processing of these femoral heads can also be done in the laboratory of a bone bank. In that case the femoral heads are prepared in a top-class level clean room with optimal controlled environmental conditions and no surgery time is needed for preparation. In **chapter 4**, we conclude that processing of femoral heads in a clean room does not reduce the number of bacteria present on the allograft bone used during the operation. We did not find any difference between the cultures of the femoral heads processed during surgery and the cultures of the bone chips prepared in the laboratory.

Several studies have shown that the allograft bone, used for BIG, can act as a carrier for antibiotics, either by impregnating the bone grafts with various antibiotic solutions or by mixing them with antibiotic powders. In **chapter 5** we confirmed the results of these

studies that it is possible to impregnate allograft bone with antibiotics and this way, achieve high local concentrations of the antibiotic, which can serve as a prophylaxis against infection. Moreover, we showed that the storage of bone chips impregnated with vancomycin or cefazolin at  $-80^{\circ}\text{C}$  does not affect the antibacterial properties. Consequently, the antibiotics can be safely added before surgery which is easier and less time consuming.

To determine the antibiotic content of the bone chips after impregnation, a dose-response curve for allograft bone impregnated with cefazolin and vancomycin was presented in **chapter 5**. Moreover, in **chapter 3** it was concluded that local use of cefazolin in a high concentration (a concentration that appeared well above the Minimal Inhibitory Concentration (MIC) for *S. epidermidis* in the dose-response curve) does not affect bone remodeling in a goat model. The amount of new bone as well as the amount of graft bone present after 12 weeks was comparable to the amount in the control group, without cefazolin.

In **chapter 6** we evaluated the air quality during 70 hip revision surgeries since prosthesis infection is often caused by bacterial contamination intra-operatively. It was hypothesized that with decreasing the number of door-openings, the air quality measured by the number of CFU/m<sup>3</sup> also decreases, which might lead to a decrease in the infection risk. We were not able to show a significant relation between these variables ( $p=0.08$ ), probably because the number of surgeries was not high enough to detect a significant relation and because the number of door-openings was already very low during the surgeries since doors were only allowed to be opened if strictly necessary. Moreover, no relation between surgery time or the number of people present during surgery and the number of CFU/m<sup>3</sup> could be found. We were not able to show a correlation between number of CFU/m<sup>3</sup>, particles and CFU/m<sup>2</sup>/hour on the sedimentation plate.

Since early visualization of increased bone resorption might be of importance for early diagnosis of bone loss, Dual-Energy X-ray Absorptiometry (DEXA) might be a tool for quantification of changes in bone content and bone remodeling after hip revision surgery with BIG. Therefore, in **chapter 7** DEXA was evaluated for the quantification of bone remodeling after hip revision surgery with BIG. However, it was concluded that the use of meshes to reconstruct the defect in combination with BIG ensures a DEXA scan less reproducible. For the quantification of bone remodeling after hip revision surgery with BIG, another method has to be used.



## NEDERLANDSE SAMENVATTING

Mechanische loslating is een van de meest voorkomende oorzaken van loslating van een primaire totale heupprothese (THP). Mechanische loslating ontstaat secundair aan een chronische, granulomateuze en inflammatoire respons. Deze wordt gestimuleerd en onderhouden door deeltjes die van het implantaat afkomstig zijn. Dit proces is complex en kan leiden tot een lokale of totale daling van de botmassa.

Na loslating van een primaire THP is een meer uitdagende heuprevisieoperatie nodig. Een van de technieken om de hoeveelheid bot rondom het implantaat te herstellen tijdens deze operatie is 'bone impaction grafting' (BIG). Met BIG worden eerst de botdefecten in het acetabulum en/of de femur hersteld met een metalen mesh, waarna deze defecten worden opgevuld met stevig geïmpacteerd gemalen allograft botchips in combinatie met een gecementeerde prothese. Het allograft bot fungeert als een steiger; nieuwe bloedvaten en bot kunnen in het allograft bot groeien. Tijdens dit proces wordt het allograft bot geresorbeerd door osteoclasten. Remodellering van het nieuw gevormde bot naar de karakteristieke volwassen botstructuur leidt tot het biologische herstel van het defect.

In dit proefschrift wordt behandeld hoe in de toekomst de resultaten van heuprevisieoperaties met BIG verbeterd kunnen worden door het behandelen van de botchips die gebruikt worden tijdens de impactie.

### Loslating en heuprevisieoperaties

Negentien tot dertig procent van het falen van protheses na een heuprevisieoperatie wordt veroorzaakt door loslating van de prothese. Indien er gebruik is gemaakt van allograft of autograft botweefsel tijdens de revisieoperatie, is de koppeling tussen osteoblast- en osteoclastfunctie minder goed. Hierdoor kan de botresorptie sneller zijn dan de botaanmaak. In het geval van BIG kan dit leiden tot een instabiel implantaat. Deze mechanische zwakte kan leiden tot loslating van de prothese. Om de balans tussen resorptie en aanmaak te optimaliseren, kunnen bisfosfonaten een rol spelen.

Er zijn verschillende studies uitgevoerd waarin het lokaal toedienen van bisfosfonaten in combinatie met allograft bot is onderzocht, maar de resultaten hiervan variëren sterk. Een overzicht van de studies die bisfosfonaten met allograft bot combineren is gegeven in **hoofdstuk 2** van dit proefschrift. Het lokaal toedienen van bisfosfonaten in een optimale concentratie kan een belangrijke rol spelen in de preventie van resorptie van het allograft

bot door inhibitie van de osteoclasten. Mogelijk zorgt dit voor een grotere stabiliteit na een operatie waarbij een prothese is gecombineerd met allograft bot om een botdefect te herstellen.

In **hoofdstuk 3** van dit proefschrift worden de resultaten van een botkamerstudie in geiten gepresenteerd. Geconcludeerd kan worden dat er een dosis-responsrelatie is tussen de lokale toediening van alendronaat en zowel de hoeveelheid nieuw bot als de hoeveelheid niet geresorbeerd bot achtergebleven in de botkamer 12 weken na de implantatie. Om de botformatie te stimuleren werd gedemineraliseerd bot (DBM) toegevoegd aan het allograft bot, maar er werd geen verschil gevonden in botaanmaak tussen allograft bot met DBM en zonder DBM.

### **Infectie en heuprevisieoperaties**

In ongeveer 0.5–3% van alle primaire THP's komen infecties voor. Na revisie-THP zijn deze getallen hoger en variëren tussen de 4 en 6%. Infectie kan een zeer ernstige complicatie zijn; patiënten hebben mogelijk meerdere operaties nodig, alsmede extra verpleegkundige hulp. In extreme gevallen resulteert het in het overlijden van de patiënt. Het verlagen van het infectierisico is een grote uitdaging. Het is belangrijk om het ontstaan en de risicofactoren voor infectie te begrijpen om in staat te zijn tot preventie van dergelijke infecties.

Het gebruik van allograft botchips voor BIG introduceert een mogelijke bron van infectie. In de meeste gevallen wordt het allograft bot wat gebruikt wordt voor BIG bewerkt op de operatiekamer tijdens de operatie. Het bewerken van het allograft bot in de operatiekamer neemt ongeveer 10 minuten in beslag en het vraagt om het gebruik van speciale instrumentaria zoals het gebruik van een botmolen. Door het kleine oppervlakte van het plenum, een ruimte op de operatiekamer met laminaire flow, worden de botchips vaak bereid buiten het plenum. Maar het bewerken van de heupkoppen die gebruikt worden voor BIG, kan ook gedaan worden in het laboratorium van een botbank. In dat geval worden de heupkoppen gemalen en schoongemaakt in een clean room met optimaal gecontroleerde omgevingscondities. Ook is er geen extra tijd nodig tijdens de operatie voor het bereiden van de botchips. In **hoofdstuk 4**, concluderen we dat, ondanks de verwachte voordelen van het bewerken van heupkoppen in een clean room, het aantal bacteriën dat aanwezig is op het allograft bot tijdens een heuprevisieoperatie niet vermindert. We vonden geen verschil in de bacteriekweken van heupkoppen die bewerkt werden tijdens de operatie en de bacteriekweken van de botchips bereid in het labotatorium.

Verschillende studies hebben aangetoond dat allograft bot dat wordt gebruikt voor BIG, kan dienen als drager van antibiotica, door het impregneren van de botgrafts met verschillende antibiotische oplossingen of door het mixen van de botgraft met antibioticapoeder. In **hoofdstuk 5** bevestigen we dat het mogelijk is allograft bot te impregneren met antibiotica en op deze manier hoge lokale concentraties te bereiken met het antibioticum, zodat het kan dienen als een profylaxe tegen infectie. Tevens hebben we aangetoond dat opslag van met vancomycine of cefazoline geïmpregneerde botchips bij  $-80^{\circ}\text{C}$  de bactericide eigenschappen van het antibioticum niet aantast.

Om de hoeveelheid antibiotica te bepalen op de botchips na impregnatie, hebben we een dosis-responscurve gemaakt voor allograft bot met cefazoline en vancomycine (**hoofdstuk 5**). Daarnaast concluderen we in **hoofdstuk 3** dat lokaal gebruik van cefazoline in een hoge concentratie (een concentratie ruim boven de Minimaal Inhiberende Concentratie (MIC) voor *S. epidermidis* in de dosis-responscurve) geen effect heeft op de botremodelling in een geitenmodel. Zowel de hoeveelheid nieuw bot als de hoeveelheid graft bot aanwezig in de botkamer na 12 weken was vergelijkbaar met de controlegroep (zonder cefazoline).

In **hoofdstuk 6** werd de luchtkwaliteit gedurende 70 heuprevisieoperaties geëvalueerd, omdat infectie van de prothese vaak wordt veroorzaakt door contaminatie met bacteriën tijdens de operatie. De hypothese was dat met daling van het aantal deuropeningen, het aantal bacteriën per  $\text{m}^3$  (CFU/ $\text{m}^3$ ) ook zou dalen, wat zou kunnen leiden tot een daling van het infectierisico. We hebben geen significante relatie tussen deze beiden variabelen kunnen aantonen ( $p=0.08$ ), waarschijnlijk doordat het aantal operaties niet groot genoeg was om tot significante resultaten te komen. Daarnaast was het aantal deuropeningen al heel laag tijdens de operaties omdat de deuren alleen geopend mochten worden indien strikt noodzakelijk. Ook vonden we geen relatie tussen het aantal personen aanwezig tijdens de operatie en het aantal bacteriën per  $\text{m}^3$ . Er werd geen relatie gevonden tussen de deeltjes gemeten tijdens de operatie, de hoeveelheid bacteriën op een sedimentatieplaat en de CFU/ $\text{m}^3$ .

Vroege visualisatie van de stijging van botresorptie na een heuprevisie met BIG zou belangrijk kunnen zijn voor snelle diagnose van botverlies. Dual-Energy X-ray Absorptiometry (DEXA) meet de botdichtheid en zou een goede methode kunnen zijn voor het zichtbaar maken van veranderingen in hoeveelheid bot en botremodelling. Het gebruik van DEXA voor het inzichtelijk maken van botremodelling na een heuprevisieoperatie met BIG werd in **hoofdstuk 7** geëvalueerd. Uit deze studie concluderen we dat, door het gebruik van een mesh om het defect te reconstueren tijdens de operatie, een DEXA-scan niet geschikt is voor de kwantificering van botremodelling na een heuprevisieoperatie.

## DANKWOORD

Mijn proefschrift is af! Maar dit had ik niet gered zonder de hulp van vele anderen. Allereerst wil ik de patiënten bedanken voor hun medewerking aan het onderzoek. Daarnaast ben ik Bislife dankbaar voor het mogelijk maken van het onderzoek en voor het sponsoren van de studie. Verder wil ik op deze plek een aantal mensen in het bijzonder bedanken.

Beste Rolf, het starten van een onderzoek bij de botbank was jouw idee, de details van het onderzoek hebben we gaandeweg ingevuld en het resultaat ligt nu voor je! Bedankt voor alle kansen die je me hebt gegeven bij de botbank en voor alle kansen die je me nu geeft in Delft. Ik heb veel van je geleerd en bewonder je passie voor de orthopedie, je eerlijkheid en je enthousiasme. Het is een voorrecht dat je mijn co-promotor bent.

Beste Pieter, vanaf het begin ben je betrokken geweest bij het onderzoek en mede dankzij het brainstormen in Nijmegen heeft het onderzoek de vorm gekregen die het nu heeft. Bedankt voor al je inzet, je snelle reacties op manuscripten, het meedenken en je interesse.

Beste Wim, de meeste van de metingen tijdens de heuprevisies heb ik tijdens jouw operaties gedaan en je humeur was altijd goed! Bedankt voor je interesse in de voortgang van het onderzoek en je opbouwende kritieken op de resultaten en manuscripten, maar ook voor de vroege berichtjes als 's ochtends bleek dat een operatie toch niet doorging, zodat ik niet naar Nijmegen hoefde te komen.

Beste Peter, bedankt voor je hulp bij het opzetten van de onderzoeken, het lezen van de manuscripten en het brainstormen over de logistieke uitvoering van de studies. Maar ook bedankt voor het creëren van een onderzoeksafdeling in Delft, waar ik in 2012 jouw functie heb overgenomen.

Rolf, Pieter, Wim en Peter, bedankt voor de inspirerende afspraken in Nijmegen, Delft of Leiden. We hadden niet vaak met deze hele groep overleg omdat iedereen ergens anders aan het werk was, maar na deze afspraken was ik altijd weer gemotiveerd om door te gaan!

Prof. dr. M.A.W. Merckx, Prof. dr. J. Jansen en Prof. dr. G.H.I.M. Walenkamp, bedankt voor het lezen en beoordelen van het manuscript.

Gerjon, je hebt me ontzettend veel geholpen; het doen van een DEC-aanvraag, het opereren van de geiten en alles wat daar bij kwam kijken, kritisch de stukken nalezen, statistiek... Heel erg bedankt voor al je hulp en je enthousiasme!

Maatschap orthopedie en traumatologie Delft: Dieu Donne, Gerald, Hennie, Joost, Max, Rolf en Stephan, heel erg bedankt voor de kans die jullie me hebben gegeven om als onderzoeker bij jullie aan de slag te gaan, ondanks dat mijn proefschrift nog niet af was. Ik heb het heel erg naar mijn zin, leer nog iedere dag veel en vind vooral jullie enthousiasme voor het vak geweldig om te zien. Petra, dank je voor je interesse en hulp, ben heel blij met zo'n gezellige collega. Nicole, jij ook bedankt voor je support, in februari ben jij klaar met je studie!

Beste Patrick en Pieter (Petit), het was heel fijn om de hulp van twee enthousiaste microbiologen te hebben voor de verschillende onderzoeken. Pieter, het in vitro onderzoek heb ik uitgevoerd in Schiedam. Je had altijd tijd om mee te denken over verbeteringen, het was fijn om dit onderzoek in het lab in Schiedam uit te voeren. Patrick, bedankt voor het meedenken met de opzet van verschillende onderzoeken en natuurlijk ook voor je kritische blik bij het lezen van de artikelen.

De in vitro studie van dit onderzoek heb ik uitgevoerd in Schiedam: de hele afdeling Microbiologie van het Vlietland Ziekenhuis heel erg bedankt voor alle hulp, maar vooral Frans voor alle uitleg en Sylvia voor het regelen van de materialen en het meedenken.

Leon en Maud, jullie hebben me veel geholpen tijdens de botkamerstudie. Maud, het was gezellig tijdens de operaties en de voorbereidingen, heel erg bedankt daarvoor. Leon, ontelbaar veel coupes snijden en handmatig tellen; wat een werk! Maar je was altijd vrolijk, ook jij heel erg bedankt voor al je hulp! Het CDL kan natuurlijk niet ontbreken, alsmede de boerderij waar de geiten na het plaatsen van de botkamers naar toe gingen. Maikel, Wilma, Alex en Conrad, jullie doen je werk met passie en liefde voor de dieren, mooi om te zien. Heel erg bedankt voor alle hulp en de gezelligheid.

Ik heb veel metingen gedaan tijdens heuprevisieoperaties in zowel Delft als Nijmegen. Alle ok-assistenten bedankt voor de gezelligheid en hulp tijdens de operaties waar ik met mijn 'stofzuiger' en kweekstokken metingen kwam doen. De resultaten van deze metingen moesten natuurlijk geanalyseerd worden en hier hebben Carla en Judith in Nijmegen en Marion en Hennie in Delft mij erg goed bij geholpen. Ook jullie erg bedankt.

Voor de DEXA-studie moet ik ten eerste Sander en Marc bedanken. Dankzij jullie inzet tijdens jullie afstudeerstages is dit artikel tot stand gekomen. Maar ook Marc ten Broek en Vincent Verhoeven van de afdeling Nucleaire Geneeskunde erg bedankt voor de DEXA en CT en voor het uitlenen van de kelder ☺. Jeanette, bedankt voor je enthousiaste uitleg van de werking van het DEXA-apparaat.

Hartelijk dank aan iedereen van de oud-NBF: Jolanda, Thijs, Mariette, Mirjam, Natascha, Tine en Simone. Het was altijd heel gezellig in het poortgebouw in Leiden, bij het hardlopen en de borrels. Hoop dat we elkaar nog regelmatig blijven zien! Lennard, jij bent dan wel geen oud-NBF, je hoort er wel bij. Bedankt voor alle fietsritjes van Leiden naar Amsterdam en andersom en voor de gezelligheid.

Jolanda en Floor, Evelien en Joost, Wendy en Sjoerd, Mariska en Klaas, Laurine en Ivo, Rinske en Sjoerd, Maartje en Roelof, Laurien en Jinze, Laura en Lodewijk, Tineke en Rutger, Annelies en Laurens, Jantina en René, Goedele en Richard: zonder goede vrienden die snappen dat je af en toe wat minder kunt afspreken was het een stuk lastiger geweest. Hoop dat we nog vaak weekendjes weg gaan, etentjes en borrels hebben!

Alle (oud-)Bramsterdammers heel erg bedankt en dan vooral Imo, Ernst, Marije en natuurlijk Bram. Door het hardlopen en de gezelligheid op de trainingen was mijn hoofd na een dag werken weer leeg en kon ik er weer tegenaan. Hoop dat er nog vele trainingen volgen, al ben ik er nu (tijdelijk) wat minder bij.

Lieve Lau en Tien, wat ben ik blij dat jullie mijn paranifmen willen zijn. Ik ken jullie al sinds het begin van onze studietijd, waarbij ik eerst bewegingswetenschappen met de een en daarna geneeskunde met de ander heb gestudeerd. Bedankt voor jullie hulp, interesse en gezelligheid, jullie zijn geweldige vriendinnen!

Schoonfamilie, jullie ook bedankt voor jullie interesse in mijn boekje. Ik kan niet garanderen dat ik in de toekomst tijdens weekendjes Oldenzaal toch niet 'even moet werken' nu mijn proefschrift af is, maar meer rust komt er zeker!

Lieve Lotte en Daniël, Niels en Imke, ik ben heel blij met jullie, fijn dat we zo'n hechte band hebben. Ik hoop dat ik nu wat meer tijd heb om met z'n allen leuke dingen te doen samen met onze kleine mannetjes.

Lieve papa en mama, bedankt voor alle kansen die jullie me hebben gegeven, voor het altijd interesse tonen en voor het oppassen als ik weer eens een heel weekend wilde werken. Maar jullie hebben me vooral geleerd om mijn hart te volgen en daar ben ik jullie ontzettend dankbaar voor.

Lieve Chiel, er zijn geen woorden voor om te beschrijven hoeveel ik aan je te danken heb. Samen met jou en Samuel kan ik alles aan, op naar de volgende uitdaging!

## CURRICULUM VITAE

Nina Mathijssen was born in Breda, The Netherlands, on 3 May 1980. After graduating from the VWO at the Katholieke Scholengemeenschap Etten-Leur she moved to Amsterdam in 1998 to study Human Movement Sciences at the VU Amsterdam. In 2000, she started the study Medicine, also at the VU Amsterdam. In 2005 and 2006 she obtained her Master's degree for both of these studies.

In 2006, Nina started working at the Netherlands Bone bank Foundation in Leiden, where she started the PhD project 'Novel perspectives to improve the outcome of bone impaction grafting in revision surgery of total hip arthroplasties'. At the Netherlands Bone bank Foundation she also worked as quality manager and from 2008 as head of medical affairs.

In September 2010, she started working as researcher at the orthopedic department of the Reinier de Graaf Groep. From January 2012, she is the research coordinator of the orthopedic department at the Reinier de Graaf Groep.

Nina lives in Amsterdam with Michiel Hulleman and their son Samuel.

